Surgical correction is accomplished with the patient in dorsal recumbency. The feathers are removed in a 2-cm diameter around the circumference of the wound and the area surgically prepped. The skin and subcutaneous tissues are debrided until healthy tissue is encountered. It may be necessary to debride devitalized pectoral muscle and affected portions of the carina of the keel. Radiosurgery may be used for hemostasis. Tissue and bone samples should be submitted for bacterial culture and histopathologic examination. The elevated origins of the pectoral muscles are sutured together over the keel or anchored to the cartilaginous portion of the keel in an interrupted horizontal mattress pattern with absorbable monofilament suture. The skin is closed in a simple interrupted or continuous pattern with monofilament suture. There is often considerable tension on these incision sites, therefore, it may be necessary to place tension-relieving sutures lateral to the incision. One method described involves placing interrupted horizontal mattress sutures through the skin and pectoral muscle tied over gauze sponges just lateral to the medial incision. The wings may be bandaged to the body to prevent extension and movement that would place additional tension on the suture site, and a restraint collar or body suit is usually necessary if auto-mutilation has occurred. Defects that are too large to close surgically may heal by second intention. Gentle irrigation and frequent bandage changes with a sterile hydrophilic dressing will assist in healing.[39]

Xanthoma

Xanthomatosis results from the accumulation of lipid-laden macrophages, giant cells, free cholesterol and variable degrees of fibrosis. Xanthomas often occur at the distal wing, but have been found in other locations as well. These masses may be locally invasive and wide margins may be necessary to completely excise and prevent recurrence. Some birds may mutilate these lesions, causing ulceration and secondary infection. Elevated serum cholesterol, trauma and genetic predisposition in some species have been implicated in the formation of xanthomas. Dietary correction may be curative in some species and in some individuals. However, very large, painful, hemorrhagic or infected xanthomas often require surgical resection.

Masses may be removed with bipolar or monopolar radiosurgery, taking care to avoid damage to remaining feather follicles and their blood supply. The site may be closed if there is enough remaining tissue or allowed to heal by second intention and bandaged with a hydroactive dressing (Figs 35.11a-g). If extensive subcutaneous tissues and bone are involved, amputation of the affected area may be necessary.[9]

Uropygial Gland

The uropygial gland is located dorsal to the tail. It is absent in Amazon parrots (*Amazona spp.*) and the hyacinth macaw (*Anodorhynchus hyacinthinus*) and may be reduced in size in some cockatiels. Disease of this gland and/or its papillae is not uncommon and surgical correction may be necessary. Absence of papilla feathers may indicate a problem with glandular function. Left untreated, a gland may rupture, causing inflammation and significant scar tissue formation. Simple impaction of the gland may respond to medical therapy and gentle expression of the contents. If the impaction cannot be alleviated by conservative therapy, small incisions may be made over the affected lobe(s) of the gland, the contents expressed, and the gland irrigated with saline. Antibiotics and analgesics may be indicated during recovery.[9] Neoplastic conditions of the uropygial gland with secondary infection occur with some frequency (see Chapter 13, Integument).

Chronic impaction and/or infection unresponsive to medical therapy and neoplasia of the uropygial gland may require surgical removal of the affected gland. The patient is placed in lateral or semi-ventral recumbency. Intermittent positive pressure ventilation and close monitoring of respiration is necessary when positioned ventrally to ensure movement of the sternum is not reduced and respiration not impaired. The head may be elevated and a pad may be placed under the tail, with the tail rectrices taped in place to elevate the sacrum and improve exposure and visualization of the uropygial gland. The surgical site is aseptically prepared. The gland is bilobed and each lobe receives its vascular supply from a vessel that branches at the cranial, middle and caudal portions of the gland. These vessels and other surrounding vessels require ligation or bipolar radiocoagulation. The gland may extend deep to the synsacrum and caudally to the insertion of the tail feathers.[9]

A fusiform incision is made via unipolar or bipolar radiosurgery around the circumference of the gland. This is initiated caudal to the papilla and continued craniolaterally along both sides of the gland. Dissection of the gland is initiated at the caudal aspect of the gland and extended circumferentially and cranially until the gland is removed. Mosquito hemostats or thumb forceps may be used to apply gentle traction on the gland, facilitating removal. The strongest attachments are associated with the muscle fibers at the cranial border of the gland. Hemorrhage must be strictly controlled by radiocoagulation, manual pressure and/or hemostatic products.[9] The deeper fascia is closed with absorbable monofilament suture in a simple continuous or interrupted pattern, depending on the amount of tension present. Subcutaneous and skin closure is routine. Extensive tissue trauma, neoplasia or

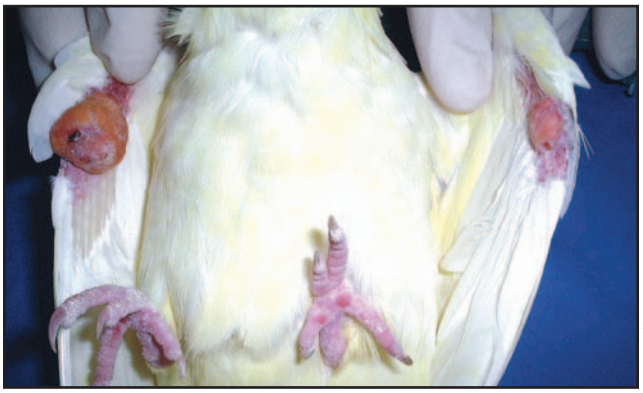

Espen Odberg

Fig 35.11a | Xanthomas often occur at the distal wing, but have been found in other locations. Note the balding plantar foot patterns and the discoloration of the feathers. These are indicative of malnutrition and related disorders.

Espen Odberg

Fig 35.11b | Xanthomas that are well demarcated and/or pedunculated may need to be excised.

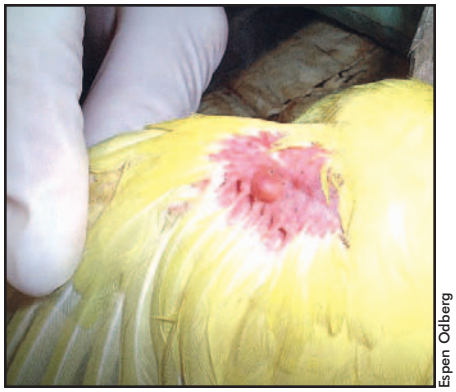

Espen Odberg

Fig 35.11c | Xonthomas that are closely associated with feather follicles may be excised, being cautious not to cause follicle damage.

Espen Odberg

Fig 35.11d | Removal of such well-defined distal wing xanthomas can be performed by making a small skin incision and gently teasing the contents out with a sterile cotton swab.

Espen Odberg

Fig 35.11e | Hemorrhage can be controlled with a bipolar or monopolar radiosurgical unit.

Espen Odberg

Fig 35.11f | After using radiosurgical hemostasis allow a few moments to make sure no oozing occurs.

Espen Odberg

Fig 35.11g | The skin is closed in a simple interrupted suture pattern with a monofilament suture.

rupture of the uropygial gland may require additional dissection and debridement. An additional caudal incision perpendicular to the dorsal midline incision may be necessary. If the remaining defect is too large to allow full closure, staged closure or healing by second intention may be necessary. Any open defects should be bandaged under a hydroactive dressing to promote granulation and prevent exposure. Antibiotics and analgesics should be administered as appropriate to each patient. Dehiscence, damage to the follicles of the rectrices and infection are potential complications (Figs 35.12a-e).[9]

Pododermatitis

Treatment and surgical intervention in severe presentations of pododermatitis are outlined in Chapter 13, Integument.

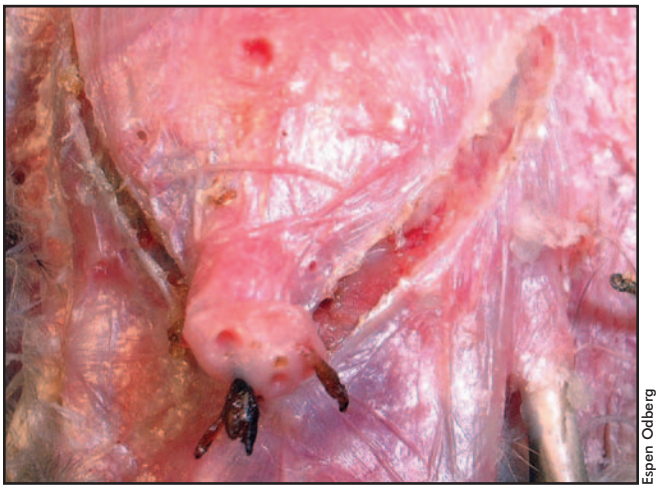

Espen Odberg

Fig 35.12a | The feathers of the uropygial gland and the feathers of the skin dorsally should be removed prior to surgical removal of the gland. Care must be taken when removing these feathers to prevent gland rupture or hemorrhage. Once the feathers of the papilla are removed, material may drain from the gland. This material will need to be cleaned and a gentle routine surgical scrub performed prior to surgery. A fusiform incision is made around the uropygial gland papilla, remaining dorsal to the tail feathers.

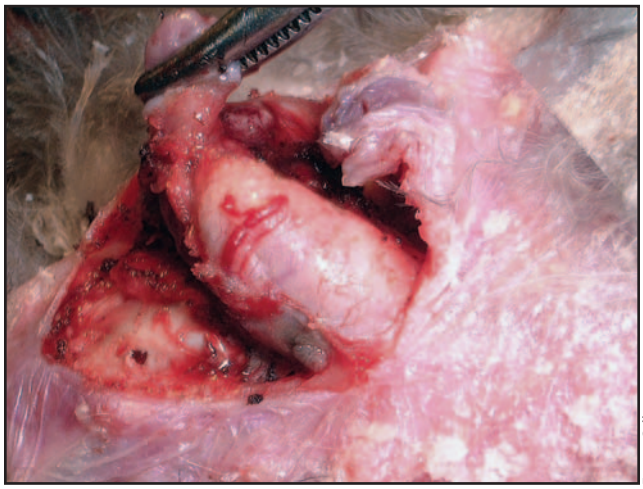

Espen Odberg

Fig 35.12b | The tissues underlying the skin are gently dissected and the skin flap is gently reflected dorsally and cranially. Hemorrhage is controlled by coagulation with a bipolar radiosurgical unit. The difference in the appearance between the left (impacted) and the right (non-impacted) side of the gland are apparent in this picture.

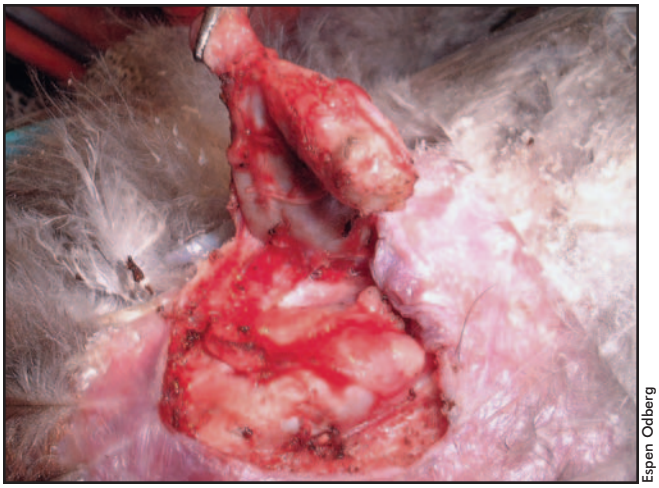

Espen Odberg

Fig 35.12c | The largest vessels of the uropygial gland are located on the cranial aspect of the gland along the muscular attachments. By utilizing the duct as a handle and working caudal to cranial, the underlying vessels can be visualized and coagulated with the radiosurgical unit. Removing the gland requires careful dissection and thorough examination for bleeding vessels.

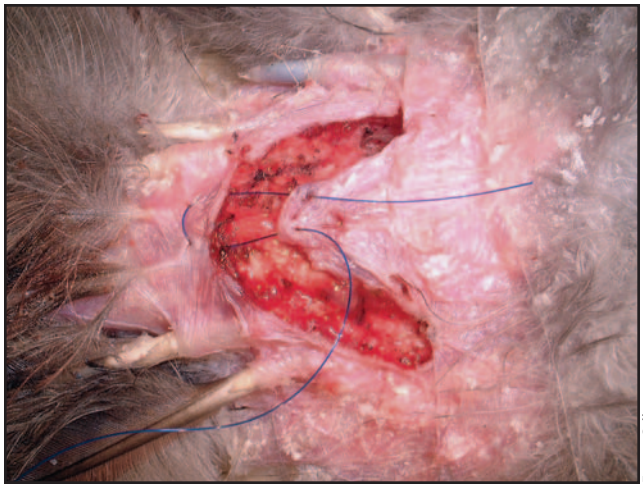

Espen Odberg

Fig 35.12d | The skin is apposed using 5-0 monofilament nonabsorbable suture. Beginning the sutures in the middle of the incision will allow for easier alignment of the skin flap.

Surgery of the Upper Respiratory System

RHINOLITH REMOVAL

Birds may develop rhinoliths secondary to chronic rhinitis and malnutrition. These masses are often formed from desiccated secretions and debris and cause a physical obstruction to respiration. The nares and opercula may become severely eroded and disfigured and damage is often permanent. Clinical signs include sneezing, upper respiratory sounds, inflation of the associated infraorbital sinus, nasal discharge and picking at the affected nares with a toenail. The nares will appear impacted with material, but it is important to recognize the normal anatomy and not mistake the operculum for abnormal material (Figs 35.13a,b). A strong light source, magnification and gentle probing may be required to identify a small rhinolith (Figs 35.14a,b). Surgical head loupes with halogen light sources are particularly useful.[1,9,71]

Nasal tissues are friable and vulnerable to traumatic

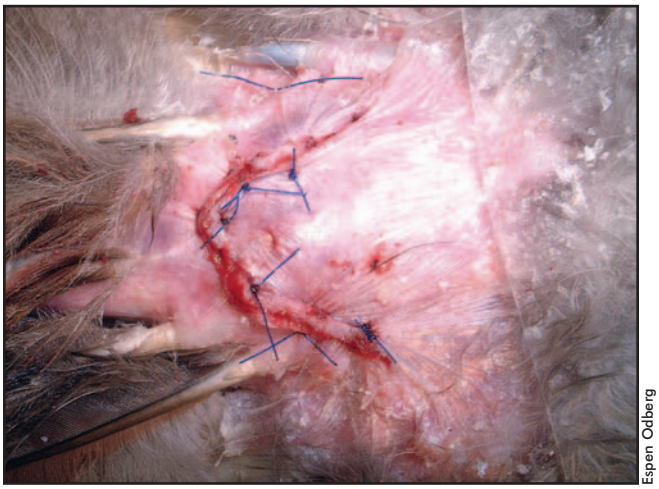

Espen Odberg

Fig 35.12e | The appearance of the incision following resection of the uropygial gland and completion of the skin closure (see Fig 35.12d).

probing, which will also predispose the mucosa to infection. Prior to attempting removal, warm saline drops should be applied to the affected naris and associated rhinolith. This will ease removal and decrease trauma to the associated tissues. A stainless steel aural curette may be used to gently elevate and remove the mass from the naris. A lacrimal cannula may be used in smaller avian patients such as budgerigars and passerines. Samples should be obtained for cytology, and bacterial and fungal culture. The nares should be flushed with a disinfectant (eg, dilute chlorhexidine or F10 solution) after removal of the bulk of the mass to remove any small pieces or material and to assist in resolution of any pathogens.[79] Appropriate antibiotic or antifungal therapy should be initiated and subsequent flushing performed. Malnutrition should be treated through diet correction. Proper air filtration, humidification and frequent bathing are necessary to prevent recurrence. The rest of the respiratory system should be thoroughly evaluated to identify other concurrent disease.[1,9,71]

INFRAORBITAL EXPLORATION AND TREPHINATION

Infraorbital sinusitis is a common disease in pet birds. This may lead to rhinitis, conjunctivitis, lacrimal infections, and if left untreated, may result in abscess and necrosis of the infraorbital sinus and osteomyelitis of the surrounding bone. Clinical signs include sneezing, nasal discharge, picking at the nares and choana with the toes, inflation of the infraorbital sinus, periorbital swelling and conjunctivitis. Hypovitaminosis A, low environmental humidity and environmental inhalant irritants may predispose birds to secondary bacterial and fungal infections. A sinus flush with sterile, non-bacteriostatic saline may be performed to obtain samples for cytology, and bacterial and fungal cultures.[1,9,71] If flushing of the sinus via the nares and other medical therapy (eg, nebulization) is not effective in establishing drainage, a surgical approach may be used.

To access the infraorbital sinus, the patient is placed in dorsal recumbency and ophthalmic lubricating ointment applied to both eyes. An incision is initiated at the rostral aspect of the infraorbital diverticulum of the infraorbital sinus midway between the eye and the external nares. It is continued caudally, staying parallel with the lateral aspect of the head. Caution must be taken not to penetrate the ocular orbit located caudally. This area is extremely vascular and hemorrhage may be controlled by the use of a laser, radiosurgery, direct pressure or commercial hemostatic products. The sinus must be thoroughly explored, as mucoid, purulent or caseous material may be located within the nasal cavity, within the beak, and between the sinus and the nasal cavity caudal to the turbinates. The sinus cavity should be well irrigated with sterile saline prior to closure and it may be necessary to remove affected periorbital bone. Closure is achieved in a simple continuous pattern with monofilament suture.[1,9,71]

Supraorbital trephination may be necessary to gain access to the dorsal and caudal areas of the infraorbital sinus, which cannot be accessed with nasal flushing and sinus aspiration. This will allow direct irrigation of these affected areas. The skin is incised to expose the frontal bone. Holes are made in the bone with a sterile rotary tool just above the eye. These holes are angled toward the midline. Cortical bone is removed until cancellous bone above the sinus is visible. Drilling is then advanced and widened to an appropriate diameter. Samples are obtained for cytology and culture, and the sinus irrigated with an appropriate solution such as saline, chlorhexidine, F10, water-soluble antibiotics and/or antifungals. The solution should pass through the choana and into the oral cavity to confirm that the trephination is accurately located. With this irrigation, fluid will enter the oral cavity; therefore, the patient should be intubated and the head positioned to allow the fluid to exit the mouth. To prevent aspiration, the oral cavity may be packed with an absorbent material to collect any excess fluid. The trephination site should be irrigated often and the site may need to be reopened, as healing occurs quickly. This procedure may be performed bilaterally, particularly in species such as passerines, in which the right and left infraorbital sinuses do not communicate. Once therapy is no longer required, the sites will heal quickly with minimal scarring.[1,9,71]

CHOANAL ATRESIA

Choanal atresia has been reported in African grey parrots

Fig 35.13a | Normal naris in a lovebird.



Fig 35.13b | Avian patients with malnutrition and subsequent squamous metaplasia and chronic respiratory infections can develop rhinoliths. Erosions of the operculum and nares may result in permanent disfigurement of the nostrils, as shown in this lovebird.

Fig 35.14a | An African grey demonstrates a mild or early stage of accumulation of debris on the operculum. Left untreated, this condition would likely progress to a rhinolith.

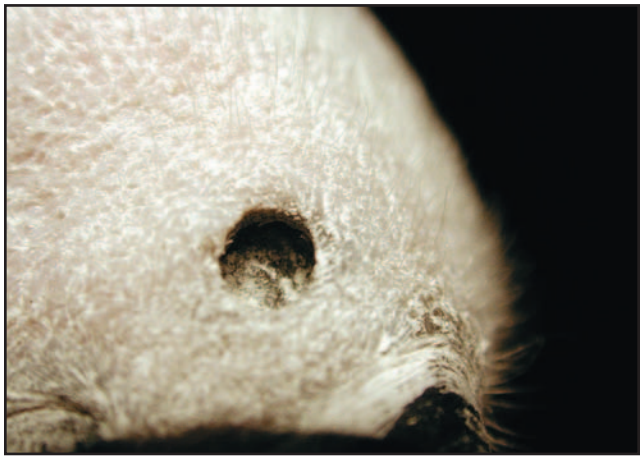

Fig 35.14b | A normal naris in an African grey on a formulated diet. Normal powder down is naturally coating the operculum, illustrating the need for showering.

(*Psittacus erithacus erithacus*) and one white cockatoo (*Cacatua alba*). The choana may either be entirely absent or there may be a membrane present that prevents communication between the nasal cavity and the pharynx. Rhinography and an endoscopic examination reveal this lack of communication.[14,36a,71]

A choanal communication may be created with the nasal cavity by hand-drilling a ⅛- or 7⁄64-inch Steinmann pin into each naris, through the nasal choanae, to enter the choana. An 8 French red rubber catheter is then passed from one naris, through the choana, and exited through the other naris. Previously cut slits in the tubing allow mucus to drain. This creates a loop of rubber tubing across the cere with each end passing through the nares to the choana. The ends are tied and secured behind the head. The tube is left in place for 4 to 6 weeks to allow formation of a permanent communication. Nasal flushes with saline are performed twice daily for 7 to 10 days to prevent mucus from occluding the holes (Figs 35.15a-n).[14,36a,71]

RUPTURE OF THE CERVICOCEPHALIC AIR SAC

Hyperinflation of the cervicocephalic air sac has been attributed to chronic infection and/or inflammation, while rupture may occur with trauma, with the former condition being more common. Location of the site of occlusion of normal air flow or rupture of the air sac in traumatic cases may not be identifiable. Smaller avian species typically suffer from generalized overinflation or rupture, while hyperinflation or subcutaneous emphysema is generally confined to the dorsum of the neck. A cutaneous Teflon stent may be surgically implanted at the highest point of the head to allow air to escape. The stent must be carefully monitored for occlusion with debris.[1,9]

A skin incision is made just large enough to insert a 5-mm Teflon stent. Sutures are pre-placed in the four pairs of holes in the flange of the stent. The suture enters the one hole from the external side, doubles back, and passes through the other hole from the lateral side. Once all four sutures are placed, the stent is implanted. A 22-gauge needle is inserted through the skin at the proper location for one end of the suture material to be inserted through the needle to be exteriorized through the skin. This procedure is repeated for the remaining three sutures and the sutures tied in place. The stent may become occluded and may require cleaning with a swab or needle. Occasionally the cervicocephalic air sac may be so excessively hyperinflated that it may interfere with prehension of food or even traumatize the cornea. Excess redundant skin may require resection after releasing the excess air and deflating the air sac.[1,9]


Don Harris*

Fig 35.15a | An African grey with epiphora from choanal atresia.

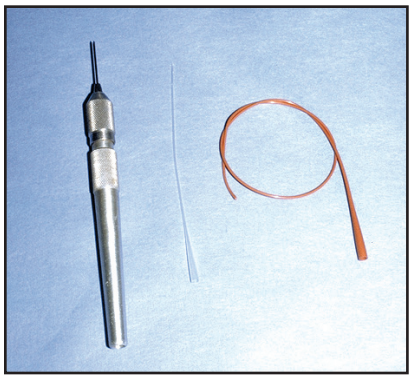
Don Harris*

Fig 35.15b | (From left to right) 0.065 K-wire, with or without the chuck, 3.5 French closed-end tomcat catheter, No. 5 French rubber feeding tube.

Don Harris*

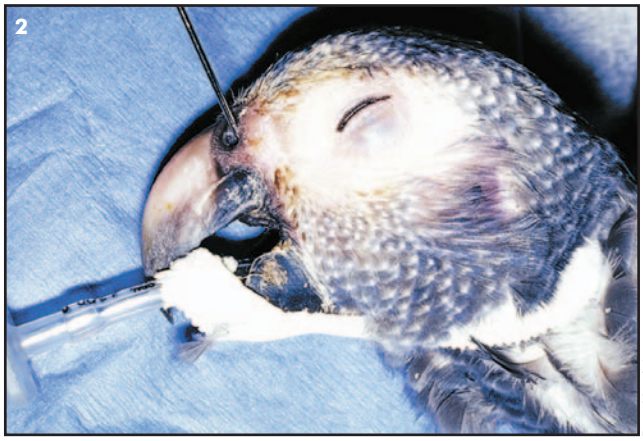

Don Harris*

Fig 35.15c1,2 | To access the nasal passageway, the K-wire pin must be introduced in a direction perpendicular to the long axis of the head. The initial approach is the most important step, as it determines the site of choanal perforation.


Don Harris*

Fig 35.15d | The tip of the pin (with or without the chuck) is introduced through the nostril beneath the turbinate. While maintaining contact with the ventral surface of the nasal cavity, the pin is angled medially until the ventral midline of the nasal cavity is encountered. The exact ventral midline must be located blindly - based on "feel." In birds that do not have an osseous blockage, the membrane can be determined by some "give" in the distal end of the pin as the midline is slowly approached. Or, instead of a soft membrane, you may encounter a "slot" in the bony tissue into which the pin tends to slip. At the midline of the ventral aspect of the nasal cavity, the pin is directed with minimal pressure and rotation to puncture through into the oral cavity.*

*Figs 35.15a-n used with the permission from Zoological Education Network.[36a]

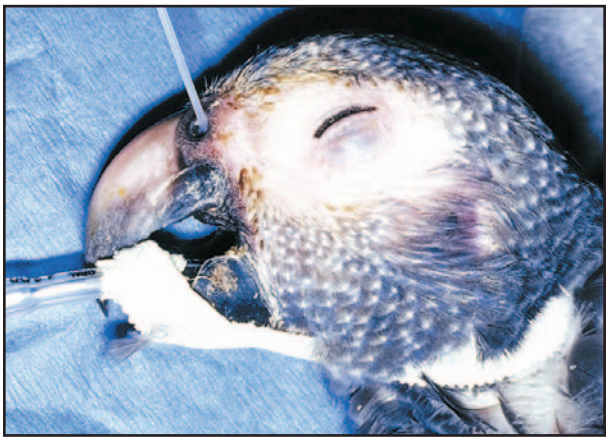
Don Harris*

Fig 35.15e | When the perforation has been made, the K-wire is removed, and a tomcat catheter is inserted into the naris and passed in the same direction into the oral cavity.


Don Harris*

Fig 35.15f | The tomcat catheter is introduced into the oral cavity with a hemostat which is used to pull it through the newly created opening.


Don Harris*

Fig 35.15g | When the catheter has been pulled most of the way through, the proximal end must be trimmed to fit through the nasal passage.

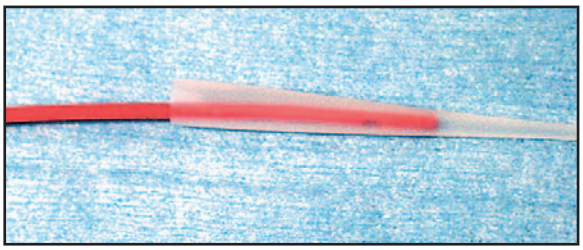
Don Harris*

Fig 35.15h | The distal end of the feeding tube is introduced into the proximal end of the catheter.


Don Harris*

Fig 35.15i | A mark is made at the point where the two join together snugly. The feeding tube is removed and the catheter is trimmed at that point.

Don Harris*

Don Harris*

Fig 35.15j1,2 | After the connection has been made, the catheter is used to pull the feeding tube through the nasal perforation and into the oral cavity.

*Figs 35.15a-n used with the permission from Zoological Education Network.[36a]


Don Harris*

Fig 35.15k | After one end of the feeding tube is introduced into one nostril, the procedure is repeated by introducing the other end of the feeding tube into the other nostril. The free ends of the tube are pulled through so that the middle of the feeding tube is retracted onto the dorsal surface of the cere.


Don Harris*

Fig 35.15l | At the point where the tube exits one nostril and enters the other, the tube itself must be trimmed to allow the passage of mucus from the nasal cavity externally. If this is not done, the sinuses fill with nasal mucus and the tube would need to be removed, drained and reinserted.

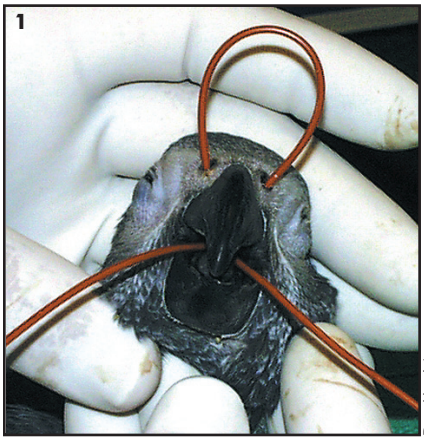

Don Harris*

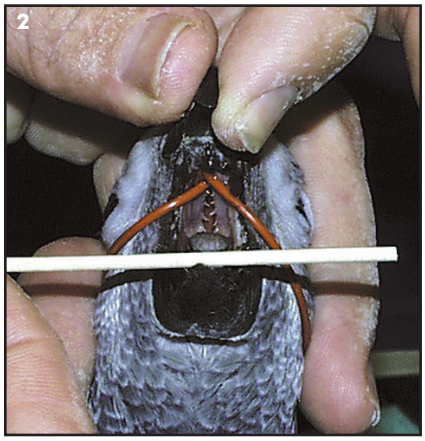

Don Harris*

Fig 35.15m1,2 | The feeding tube actually creates a figure 8 configuration where one end enters the left nostril and comes out the right side of the mouth; the other end of the feeding tube enters the right nostril and exits the left side of the mouth. The ends are tied behind the bird's head.


Don Harris*

Fig 35.15n | A chin strap can be devised to help hold the tube in place.

*Figs 35.15a-n used with the permission from Zoological Education Network.[36a]

Placing a one-way valve connecting the cervicocephalic air sac to the clavicular air sac may also be used to treat rupture of the cervicocephalic air sac. An approach is made through the left lateral thoracic inlet. The tube is inserted into the hyperinflated air sac, directed caudally along the esophagus, through the thoracic inlet, and into the cranial aspect of the clavicular air sac. The tube is sutured to the *longus coli* muscle to prevent migration, but no attempt is made to suture the air sac around the tube. Skin closure is routine. This method does pose a risk associated with leaving a foreign object in the body. The risk/benefit ratio should be considered prior to surgery, as many birds function well with a persistently hyperinflated cervicocephalic air sac.[1,9]

Air sac hyperinflation may be treated by an alternative procedure that may be used alone or in combination with those previously described. This procedure is particularly useful if the hyperinflated air sac poses a mechanical obstruction to respiration, food intake and physical movement. The air is removed by making a small incision in the overlying skin and air sac, thereby deflating and collapsing the air sac. Redundant skin and air sac are excised, and the skin and air sac sutured to the underlying tissue in several places to prevent extensive re-inflation. The surgical site is closed with a simple continuous pattern using monofilament suture. Traumatically induced subcutaneous emphysema may be alleviated by surgically incising the site to remove the excess air from under the skin.

Although postsurgical subcutaneous emphysema is possible, it is uncommon even in birds that have undergone extensive surgery to the air sacs and associated bone.[1,9]

Thoracic Surgery

TRACHEAL OBSTRUCTION

Foreign material such as seeds, granulomas, inflammation, scarring post-trauma, or concretions of epithelial cells and mucous may occlude the trachea or syrinx, resulting in respiratory distress. Clinical signs include respiratory distress, dyspnea and vocal change. A history of recent anesthesia and intubation should raise concern regarding iatrogenic tracheal trauma, particularly if the endotracheal tube cuff was inflated. Foreign material may be visible in the trachea by wetting the overlying feathers with alcohol and transilluminating the trachea. Often foreign material is located at the syrinx or main bronchi, and therefore may not be visible during an examination. The trachea also may be assessed and obstruction diagnosed with both radiographs and tracheoscopy.[9,14,18,71]

Treatment varies with the severity of the disease, size of the patient and anatomy of the trachea. Certain species such as swans and cranes possess elongated, tortuous tracheas with portions being located within the thorax, making access to the distal trachea difficult. Emergency treatment includes oxygen supplementation and possible placement of an air sac cannula to create a patent airway and stabilize the patient prior to further care. Please refer to Chapter 7, Emergency and Critical Care for a complete description regarding placement of air sac cannulas in birds. An appropriately sized needle may be temporarily placed through the trachea just distal to the foreign body or granuloma to prevent distal migration of the obstructing material, particularly during endoscopic retrieval or debridement. In certain avian species, the pessulum, a midline syringeal cartilage, may be present, which may impede access to a syringeal or bronchial foreign body or granuloma.[1,9,14,18,71]

Many foreign bodies may be retrieved and infectious or inflammatory granulomas may be debrided via tracheoscopy. This is an effective and minimally invasive procedure that should be pursued prior to tracheotomy. Establishment of a patent airway is necessary for respiration and anesthesia. An air sac cannula should be placed until the obstruction is removed. If the obstruction is due to a granuloma or inspissated material and mucus, a small tube such as a urinary catheter or an endotracheal tube may be advanced to the point of obstruction and used to attempt aspiration of the foreign material. Samples should be submitted for cytology, bacterial and fungal cultures. Appropriate antibiotics, antifungals, and nebulization should be continued post-operatively until resolution is achieved.[1,9,18,71,84]

If unsuccessful, or if the patient's trachea is too small to allow passage of an endoscope, a tracheotomy may be necessary. The patient is placed in dorsal recumbency and the area from the mandible to 1 to 2 cm distal to the thoracic inlet is surgically prepared. A transverse tracheotomy of approximately 50% of the tracheal circumference is performed on the ventral tracheal surface. The entire tracheal diameter should not be transected in order to maintain its anatomic alignment, reduce tension on the surgical closure and prevent disruption of the vascular supply. Stay sutures are placed around the tracheal rings adjacent to the tracheotomy site to atraumatically manipulate the trachea. Foreign material may be grasped and removed, gently debrided, suctioned, or material cranial to the incision may be pushed cranially to exit through the glottis. Simple interrupted sutures are preplaced to incorporate one to two tracheal rings on each end of the incision using small, absorbable monofilament suture. Knots are tied external to the tracheal lumen to prevent granuloma formation intratracheally. If the trachea completely separates during the procedure, an anastomosis may be performed in the same fashion, closing the entire circumference of the trachea. Soft tissue, subcutaneous and skin closures are routine (Figs 35.16a-f).[1,6,7,9,14,18,71,84]

Due to the predilection of masses and foreign bodies to be located at the level of the syrinx, surgery is often focused on the thoracic inlet. An operating microscope or halogen-illuminated magnification head loupe is necessary for optimal visualization. The patient is positioned in dorsal recumbency and gas anesthesia is delivered via an air sac cannula. A sterile swab or feeding tube should be placed in the esophagus to facilitate identification and avoid iatrogenic trauma. The skin is incised from the right clavicular-sternal junction to the clavicular-coracoid junction just lateral and ventral to the crop. The overlying skin is gently elevated from the crop and the surrounding tissues bluntly dissected from the crop to avoid tearing the crop or transecting surrounding blood vessels. Once the crop is freed from its clavicular attachments it should be reflected to the left. The trachea is identified by its complete cartilaginous rings. The sternotracheal muscles traverse obliquely and are transected near their caudolateral tracheal attachments. A large blood vessel lies between the muscle bellies and should be coagulated prior to transection of the muscles.[1,6,7,9,14,18,71,84]

Once access to the thoracic inlet has been achieved, it is helpful to elevate the cranial end of the restraint board to improve visualization deep into the thoracic inlet. The interclavicular air sac is bluntly dissected. A blunt hook is looped under the syrinx at the tracheal bifurcation and gently pulled cranially for better visualization. Tracheotomy, foreign body retrieval, granuloma debridement and closure are as described previously.[9]

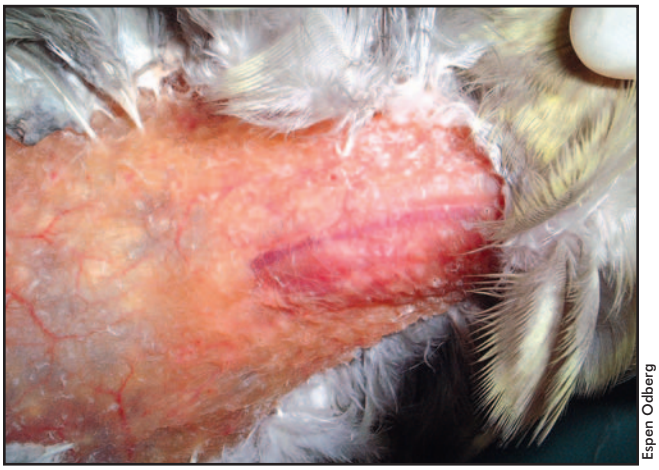

Espen Odberg

Fig 35.16a | Surgical preparation for tracheal surgery involves placing the patient in dorsal recumbency. The area from the mandible to 1-2 cm distal to the thoracic inlet is surgically prepared by removing the feathers and scrubbing the skin with an appropriate presurgical scrub.

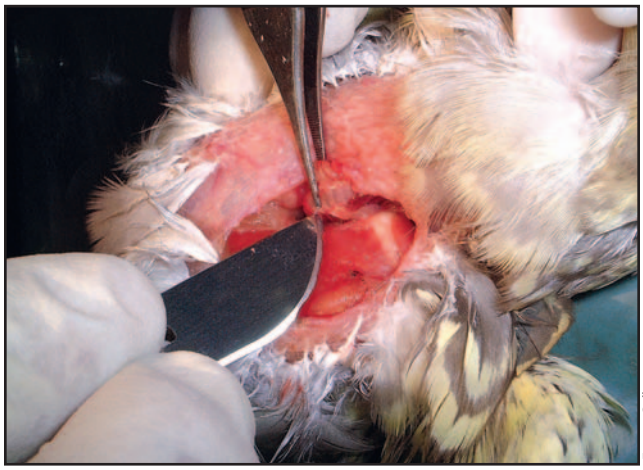

Espen Odberg

Fig 35.16b | A transverse tracheotomy incision is made on the ventral trachea, approximating 50% of the tracheal circumference.

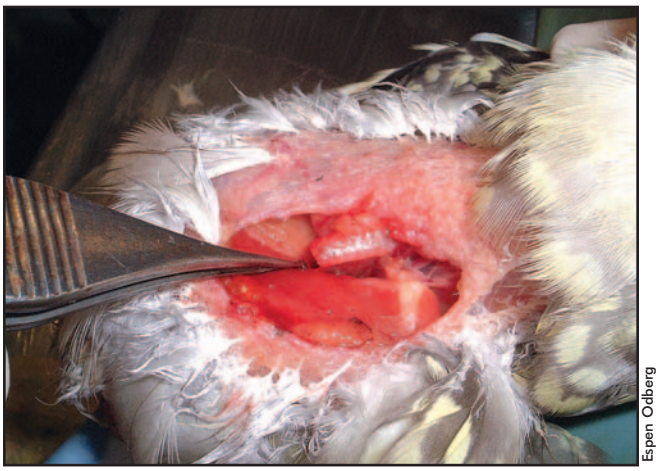

Espen Odberg

Fig 35.16c | Care should be taken not to exceed 50% of the tracheal circumference with the tracheotomy incision. This is critical in order to maintain anatomic alignment, reduce tension on the surgical closure and prevent disruption of the vascular supply.

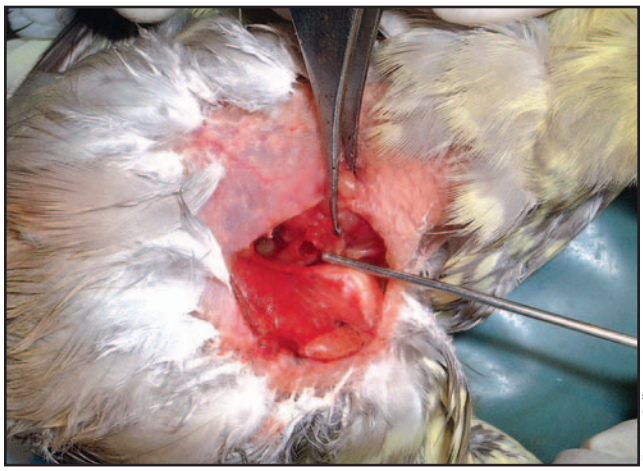

Espen Odberg

Fig 35.16d | A small-diameter endoscope can be inserted into the trachea to identify foreign material.

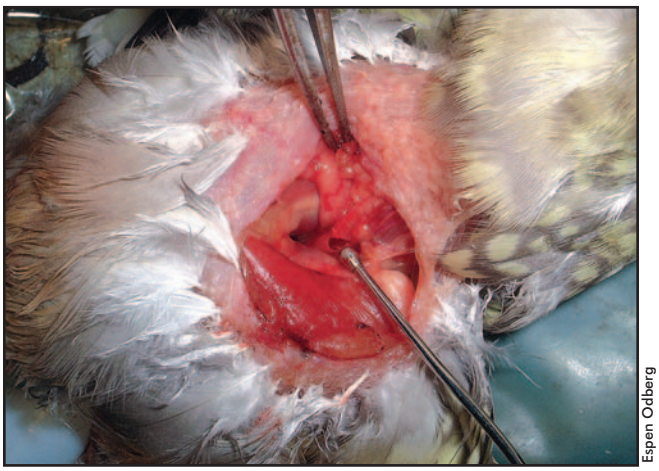

Espen Odberg

Fig 35.16e | A small-diameter suction tip, feeding tube or endoscope can be inserted into the trachea and gentle suction applied to remove any aspirated material.

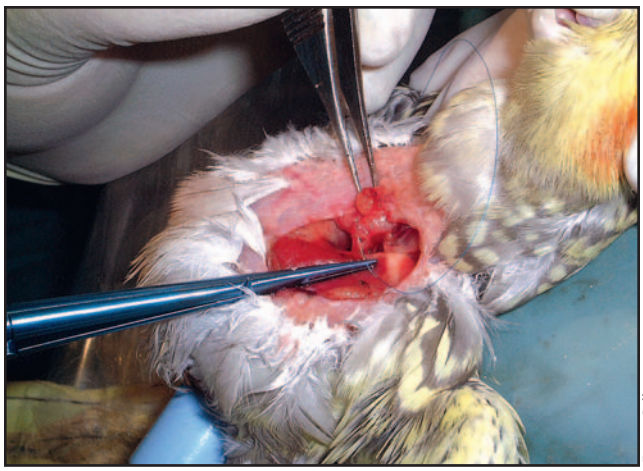

Espen Odberg

Fig 35.16f | Simple interrupted sutures are pre-placed to incorporate one or two tracheal rings on each end of the incision using small, absorbable monofilament material. Knots are tied external to the tracheal lumen to prevent granuloma formation intratracheally. If the trachea completely separates during the procedure, an anastomosis may be performed in the same fashion, closing the entire circumference of the trachea.

Certain species such as Amazon parrots, small macaws and smaller birds have shorter primary bronchi, and cranial retraction of the syrinx may result in avulsion of the bronchi from the lung. Therefore, a left lateral approach to the syrinx may be preferable. The patient is positioned in right lateral recumbency. An incision is made over the second and third ribs. These ribs are exposed by blunt dissection and transected at both ends to allow complete removal. This will expose the cranial portion of the lung. The cranial portion of the lung is gently dissected and reflected from its attachments with a moistened cotton-tipped applicator. The jugular vein, pulmonary artery and branches of the subclavian artery are then identified and should be avoided. Dissection between these vessels is performed to access the syrinx. A 2- to 3-mm incision is made in the syrinx using bipolar radiosurgical forceps at the junction with the left primary bronchus. A foreign body may be removed or granuloma debrided via tracheoscopy, suction or gentle manual removal. The syringeal incision heals by second intention. The lung is repositioned into its normal anatomic position and the ribs are not replaced. Soft tissue, subcutaneous and skin closure are routine.[1,9,71]

PNEUMONECTOMY

Surgical removal of lung tissue is indicated for biopsy and for removal of abscesses, granulomas and primary lung neoplasia. Biopsy of lung tissue may be performed by endoscopy. This is an effective and less invasive procedure if the desired site for biopsy is accessible via laparoscopy. There is no discrete pleural space in birds and the visceral and parietal pleura are in close approximation. The dorsal pulmonary parenchyma is contoured tightly to the ribs and intercostal spaces, which facilitates the surgical approach. The avian lung is more vascular and the intrinsic clotting mechanism appears to be less efficient, as compared to mammals, therefore, hemorrhage is a concern.[1,9]

The patient is placed in right or left lateral recumbency, depending on the site desired for biopsy, and the surgical area prepared routinely. A lateral celiotomy is performed. The lungs may be approached through the caudal thoracic air sac or through the intercostal space by removing one or two ribs. The affected lung tissue is carefully elevated using a sterile, moistened cotton-tipped applicator and isolated using vascular or hemostatic clips. The tissue is excised between the clips, leaving them with the viable portion of the lung for hemostasis. No studies exist to determine the amount of lung tissue that may be safely removed or the physiologic effects of pneumonectomy. However, clinically, patients appear to recover well after partial pneumonectomy. Closure includes apposing the intact ribs with stainless steel suture, cerclage wire or non-absorbable monofilament suture. If a caudolateral thoracotomy has been preformed and a portion of the last rib had to be removed for maximum exposure, resulting in unsuitable tissue to close the musculature, a stitch surrounding the remaining rib, passing caudally to and around the ipsilateral pubic bone can produce the tension needed to bring the tissues into apposition. Skin closure is routine.[1,6,7,9]

AIR SAC GRANULOMA RESECTION

Air sac granulomas are usually identified via radiographs, endoscopy or occasionally by ultrasound. If resection is indicated, a celiotomy is performed based on the relative location of the granuloma (see Celiotomy under Surgery of the Gastrointestinal Tract below).

Surgery of the Gastrointestinal Tract

ORAL CAVITY

Keratinized cysts, abscesses, oral papillomas, neoplastic masses and traumatically induced wounds may be found on the tongue, choana, glottis, submandibular cleft and salivary glands. Chronic vitamin A deficiency may result in the accumulation of keratin within cyst-like structures and the formation of caseous abscesses in the oral cavity, submandibular skin and salivary glands.[73] These may interfere with respiration and swallowing. If respiration and food intake are not compromised, it may be beneficial to perform a fine needle aspirate to obtain samples for cytology, bacterial and fungal cultures. Appropriate antibiotic, antifungal and parenteral vitamin A therapy may reduce the size of the abscess and promote encapsulation, thereby reducing the size and vascularity of the mass to be removed. Medical treatment listed previously, including supplementation with beta-carotene, has occasionally been reported to resolve these abscesses.[1,9,73]

Submandibular abscesses may be resected by incising the skin overlying the masses on the ventral neck. Abscesses within the oral cavity may be less accessible and extremely vascular. It is important to intubate these patients to prevent blood and debris from entering the airway, and pre- and postoperative endoscopic examination is helpful to fully assess the oral cavity and choana. Radiosurgery or laser may be used to incise the abscess and to control hemorrhage. The contents of the abscess are removed and the site irrigated with an appropriate disinfectant. If present, the capsule should also be resected if this can be accomplished without clinically significant hemorrhage. Samples are collected for cytology, histopathologic examination, bacterial and fungal cultures. The remaining defect is left to heal by second intention. Abscesses or cysts located on the palatine area

and choanal slit may be removed in the same manner. This area is extremely vascular and hemostasis is crucial to prevent severe hemorrhage. Some surgeons recommend temporary ligation of the palatine arteries during the procedure.[1,9,73]

Papillomatous masses may be removed from the choanal slit, glottis or pharynx with radiosurgery, laser or cryosurgery. Removal with chemical cauterization must be carefully controlled to prevent severe damage to adjacent tissues. Excision is usually not curative and recurrence is common. Papillomatous masses are often located in other regions of the gastrointestinal tract and cloaca. Hepatic and pancreatic carcinoma are associated with papillomatosis. The reader is referred to other sections of this text for a thorough description of papillomatosis and associated disease conditions (Figs 35.17a-c, 35.18a-c).[1,9,73]

Traumatic injuries to the tongue may result in significant hemorrhage, pain and failure to eat. If topical anticoagulants and chemical cautery fail to control hemorrhage, a mattress suture may be placed with an absorbable monofilament suture. The knot of the ligature is placed on the ventral surface of the tongue.[73]

Neoplasia of the tongue has been reported. These masses may be removed by radiosurgery or laser.[73] Complete excision with adequate margins may be difficult and it may be beneficial to ablate the surrounding tissue. A feeding tube or frequent tube-feeding may be necessary for alimentation.

PHARYNGOSTOMY

A pharyngostomy is most often performed in order to place a feeding tube. This is indicated if the patient is anorectic, or if it is necessary to bypass the oral cavity, the esophagus and/or the crop. The patient is placed in left lateral recumbency and the right side of the neck is surgically prepped from the caudal aspect of the mandible to the midcervical region. A small incision is made through the skin and the underlying esophagus is identified. A moistened cotton-tipped applicator or mosquito hemostat is inserted through the mouth and pharyngeal region and visualized through the skin. A small 1- to 2-mm incision is made over this swab in an avascular area. The tube is grasped with the ends of the mosquito hemostat to facilitate entry into the crop and advanced through the lower esophageal sphincter to the proventriculus, depending on the location of the pathology or disease condition that necessitated placement of the feeding tube. The external end of the tube is then sutured in place with two simple interrupted sutures, incorporating the skin and esophageal crop wall on both sides of the incision. The area is bandaged to protect the site, directing the external portion of the tube dorsally to prevent it being chewed or manipulated by the patient. When no longer needed, the sutures are cut and the tube removed. The esophagus/crop and skin can be left to heal by second intention.[1,9] A step-by-step pharyngostomy is shown in (Fig 35.19a-g); the procedural details are similar to those used in other species.

ESOPHAGEAL PERFORATION

Esophageal perforation may be caused by the use of a firm feeding tube, struggling of the patient during tube-feeding, enthusiastic feeding response while a feeding tube is inserted into the crop, or thermal burns followed by necrosis with or without fistulation. Food may enter the subcutaneous space through the lacerated or necrotic esophagus. Severe edema, infection, sepsis, toxemia and necrosis may result. Rapid emergency and supportive care must be instituted. Surgical repair will vary according to the extent of tissue damage, necrosis and infection (see Chapter 14, Evaluating and Treating the Gastrointestinal System, Figs 14.12a-f). The patient is placed in dorsal or lateral recumbency, depending on the location of the tissue damage, and repositioning may be necessary to gain access to all affected areas. A skin incision is made through the overlying skin with a blade, monopolar or bipolar radiosurgery, or with a laser. The subcutaneous and underlying esophagus is then examined to determine the extent of disease. If affected tissues appear healthy, immediate debridement, irrigation and closure may be possible. However, often these patients are diagnosed days to weeks after the initial perforation occurred and severe necrosis and infection are present. These patients may require multiple debridements and irrigation procedures. The external affected area should be bandaged with hydrophilic dressing to promote tissue granulation. Final surgical closure must be delayed until the necrotic tissue has been delineated and resected. Once this is achieved, the esophagus may be closed in a simple continuous inverting pattern, and the subcutaneous and skin closure is routine. A pharyngostomy tube may be placed extending through the lower esophageal sphincter to bypass the esophagus during feeding until the esophagus is healed.[1,9]

CROP BURN REPAIR

Thermal crop damage with or without fistula formation may occur when overheated juvenile feeding formula is stored within the crop immediately after feeding. These thermal burns may range from minor and inapparent to severe and life threatening. The extent of tissue injury and necrosis may not be evident for several days to weeks. An attempt at immediate surgical repair may fail due to progressive tissue necrosis. With severe or extensive crop burns, the patient is often both septic and toxic.


Espen Odberg

Fig 35.17a | A macaw with severe oral papillomatosis. The choanal slit is occluded with hypertrophic tissue, as is the majority of the oropharynx.

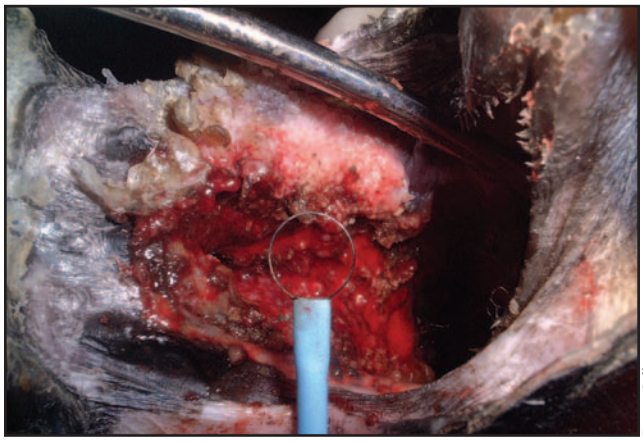
Espen Odberg

Fig 35.17b | A loupe-monopolar radiosurgical tip can be used to debulk oral masses. Care must be taken not to damage adjacent tissues.


Espen Odberg

Fig 35.17c | Silver nitrate can be used to debulk oral papillomas, but care must be taken not to cause chemical damage to adjacent structures within the oral cavity.

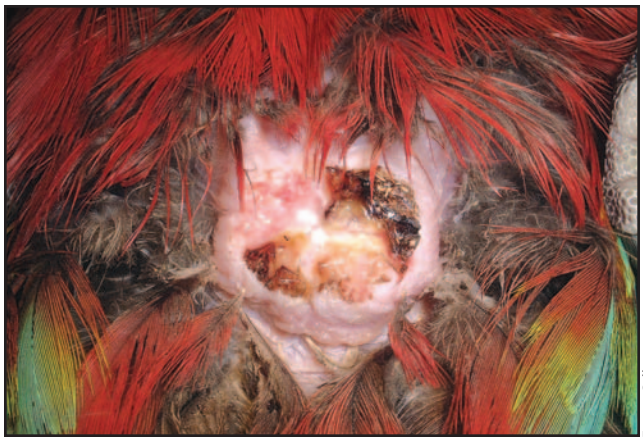
Espen Odberg

Fig 35.18a | Papillomas may be found on the mucosal surface of the cloaca, oropharynx, esophagus/crop, proventriculus, ventriculus, bile ducts and pancreatic ducts. Cystic regression and recurrence is extremely common, and *E. coli* and *Clostridium* spp. are often isolated from the cloaca of affected birds. Surgical resection is recommended, particularly if the mass is causing straining to defecate, secondary cloacal infection, fecoliths, hematochezia, and cloacal prolapse.


Espen Odberg

Fig 35.18b | Cloacal papillomas may be visualized by applying gentle pressure to either side of the vent. Insertion of lubricated cotton-tipped applications may aid in eversion of the cloacal mucosa and allow visualization of the prominent papillomatous tissue. Papillomas are identified by a characteristic "cobblestone" appearance of the mucosa.


Espen Odberg

Fig 35.18c | Methods for removal of cloacal papillomas include silver nitrate cauterization, cryosurgery, radiocautery, laser surgery, and blade excision. The mass and affected cloacal wall may be everted manually and the mass debulked with any of these methods. If silver nitrate is used, as in this photo, the area must be thoroughly flushed with saline to prevent cauterization of normal mucosa as soon as sufficient tissue has been cauterized to debulk the mass.

Pharyngostomy – step by step Figs 35.19a-g


Scott Echols

Fig 35.19a | The length of the tube to be used is determined by measuring from the crop to the level of the proventriculus.

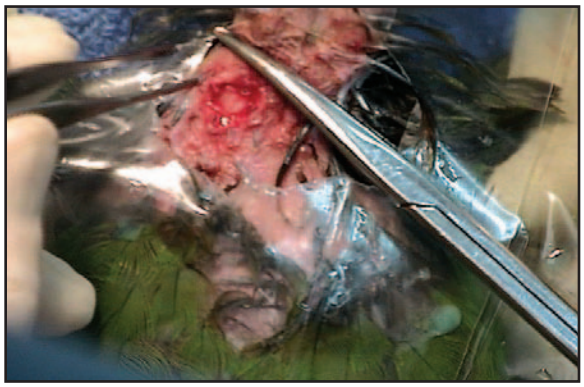
Scott Echols

Fig 35.19b | The skin over the crop is incised.

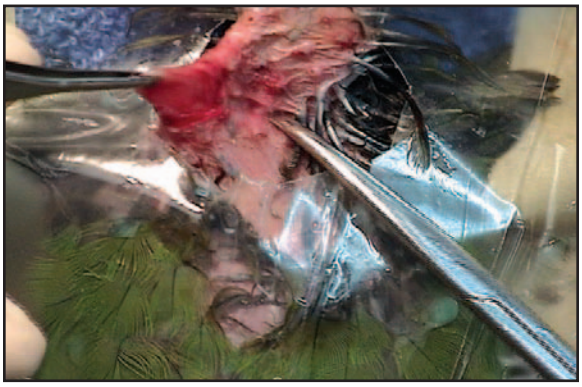
Scott Echols

Fig 35.19c | The crop tissue is exteriorized and incised just enough to allow tube insertion.

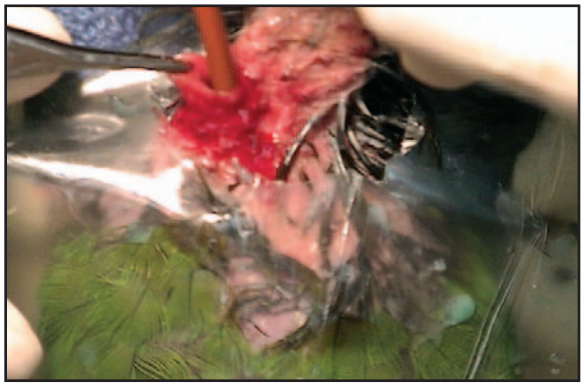
Scott Echols

Fig 35.19d | The tube is placed in the crop and slowly advanced toward the thoracic inlet just ventral to the trachea. The surgeon's index finger guides the tube within the esophagus, using the trachea as a guide, advancing into the thoracic esophagus and proventriculus.

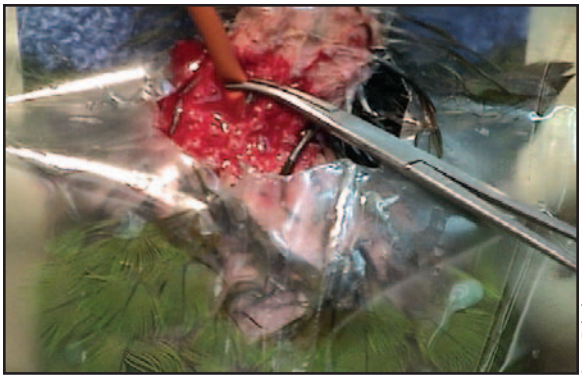
Scott Echols

Fig 35.19e | The tube is positioned for suturing.

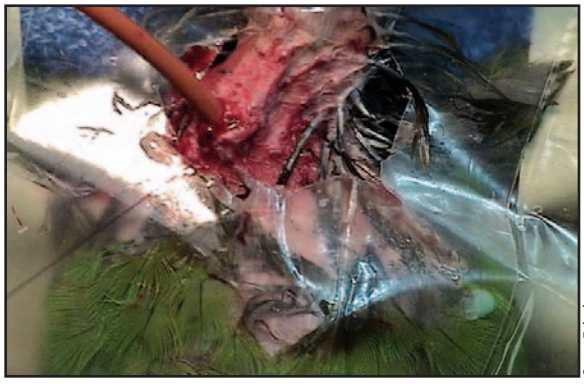
Scott Echols

Fig 35.19f | A purse-string suture is placed around the tube to prevent crop contents from leaking.

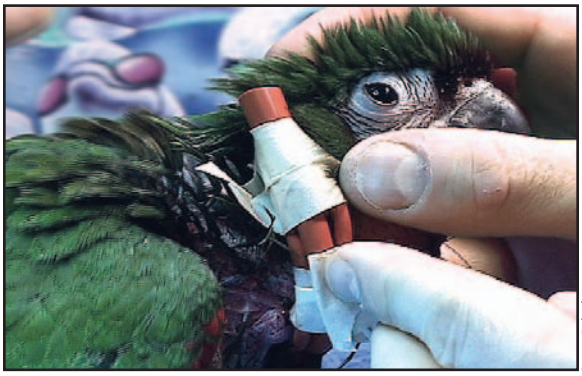
Scott Echols

Fig 35.19g | The tube is coiled alongside the head. A bandage is applied that allows syringe access, but prevents the bird from pulling or scratching out the tube.

Despite aggressive medical therapy, some of the patients will succumb within the first hours to days following presentation. Patients in this condition are not surgical candidates. Therefore, topical treatment, hydrophilic bandaging and supportive care are indicated. If a fistula occurs prior to delineation of the affected area and the establishment of a granulation bed, it is important to initiate supportive care. A pharyngostomy tube must be placed if the fistula is large enough as not to allow any appreciable food storage or if weight loss is documented. Otherwise the bandage covering the region may assist in containing the formula.[1,9] Medical treatment alone may resolve less severe burns, with shrinkage of the scar tissue closing the potential deficit. When the fistulated area has begun to granulate, then surgical repair should be performed.[1,9]

The patient is anesthetized and placed in dorsal or lateral recumbency, depending on the location of the fistula. The area and surrounding skin are prepared aseptically. Do not use alcohol, as it may gain access to the esophagus and damage the serosa. A circumferential incision is made around the edges of the fistula and the adhered skin is separated from the ingluvies by blunt dissection. Care should be taken not to extend the fistula more than is necessary for removal of necrotic tissue. Placement of a tube or swab into the esophagus from the oral cavity will aid in the delineation of the crop. It is important to note that the skin is normally attached to the crop by two layers of striated muscle that form a sling-like support for the diverticulum of the crop. Once the crop is separated from the skin, the crop is closed in a simple continuous inverting pattern and the overlying skin closed in a simple continuous pattern. The skin and crop should be closed in two separate layers, as there is an increased risk of dehiscence if the two layers are closed together **(Figs 35.20a-e)**.[1,9]

Occasionally thermal burns are so severe that very little viable tissue remains. The length of the crop should be maintained if possible. Esophageal strictures are more likely to develop if resection and anastomosis are performed than if only a thin strip of esophageal tissue is preserved and allowed to granulate over a stent. If enough viable tissue is present, it may be sutured over a pharyngostomy tube. A longitudinal incision with a transverse closure will increase the diameter of the esophagus and may reduce the risk of esophageal stenosis. The patient must receive frequent small feedings of a soft or liquid diet until the crop stretches and the holding capacity increases. If there is not enough viable esophageal tissue present to close the defect, it may be allowed to heal by second intention while a pharyngostomy tube is in place. Alternatively, a dermoplasty may be performed once healthy granulation tissue is present. A rotating skin flap will usually cover the defect.[1,9]

INGLUVIOTOMY AND CROP BIOPSY

Pet birds, particularly neonates, are susceptible to ingestion of foreign materials. Feeding tubes, substrate and small toys are commonly ingested. The foreign materials will obstruct food passage and irritate the crop. Small objects may be retrieved from the crop by esophagoscopy or by manual retropulsion and withdrawal with a hemostat or tissue forceps. Manual retropulsion is noninvasive, but may result in inadvertent concurrent retropulsion and subsequent aspiration of liquid from the crop. Care must be taken not to damage the crop, esophagus, pharynx, oral cavity and choana, and a thorough examination of all structures should be performed after retrieving the object to note any trauma or remaining pieces of material. An endoscopic exam of the oral cavity, choana, pharynx, esophagus and crop after removal of foreign substance is useful to determine if there is any damage to these structures.[1,9]

Indications for an ingluviotomy include foreign body retrieval, endoscopic access to the proventriculus and ventriculus, or biopsy of the crop for histopathologic evaluation. The patient is placed in dorsal recumbency and skin prepped routinely. It is important that the patient be intubated and, if there are contents within the crop, it is recommended to occlude the upper esophagus with a moistened gauze sponge to prevent any refluxed ingesta from entering the airway. An incision is made through the skin over the left lateral portion of the crop. This may be performed by scalpel, monopolar or bipolar radiosurgery, or with a laser unit. The skin is bluntly dissected to identify the crop. Stay sutures are placed in the crop wall to assist in manipulation of the crop, facilitate incising the crop and to prevent uncontrolled exit of material within the crop. The crop is then incised at the cranial aspect of the left lateral side of the sac. This area of the crop is less prone to stress as the crop fills and is not within the path of a feeding tube should the patient require tube-feeding postoperatively. This crop incision should be made with a scalpel blade or sharp scissors to preserve the integrity of small blood vessels. Radiosurgery should be used only to coagulate vessels. If the ingluviotomy is being performed for foreign body retrieval or for access to the proventriculus and ventriculus for an endoscopic exam, the incision into the crop should be performed in a relatively avascular region to control hemorrhage. If the purpose is to collect a biopsy of the crop for histopathologic examination—such as those performed as part of a diagnostic workup in patients demonstrating clinical signs consistent with proventricular dilatation disease—this biopsy should be collected from a vascular region, as it is crucial