

Advances in

# Diagnostic Imaging

PETER HELMER, DVM, Dipl. ABVP-Avian




Advances in technology have resulted in many different ways of producing and recording diagnostic images. Conventional black and white radiographic images on film continue to predominate, primarily due to widespread access, ease of use, familiarity and relatively low cost. Digital and computerized radiographic images are not widely accessible in private practice. These latter modalities produce a digital image that can be manipulated with a computer to highlight detail and compensate for less than ideal technique settings. Digital technology will become more affordable and more readily available to the private practitioner in the future.


## Radiographic Technique

The diagnostic value of a radiograph is directly proportional to the quality of the radiograph. The small size and fine detail of the avian patient necessitate excellent-quality images. Multiple factors influence the quality of a radiograph.<sup>20</sup> These factors include motion, the speed of the film, focal spot size, focal spot-to-film distance, object-film distance, the use and type of intensifying screen, and the use of a grid. No technique can maximize the benefits of all of these factors, but a reasonable compromise can be obtained that results in radiographs of high quality.

Motion, even in small amounts, results in significant blurring of the image. In order to minimize this artifact, patient restraint is required. Physical restraint of the avian patient for radiography is rarely adequate. Proper positioning of the awake patient is difficult. There is



**Fig 25.1** | Mammography cassette<sup>a</sup> opened to reveal the single intensifying screen.



**Fig 25.2** | Mammography film<sup>b</sup> has a single-sided emulsion. When loading cassettes, the light side of the film should be in contact with the white side of the cassette.

significant stress and risk of injury to the bird, as well as increased risk of radiation exposure for the handler. Restraint in the form of inhalant anesthesia (isoflurane or sevoflurane) is strongly recommended. The risk of general anesthesia should be assessed for each patient, but usually this risk is far outweighed by the benefits of decreased patient stress, increased quality of the radiographs, less time spent by staff, less exposure to radiation and fewer patient injuries.

Respiratory motion is largely unaffected by appropriate planes of anesthesia. Avian respiratory rates require relatively short exposure times to eliminate the motion artifact. In practice, exposures of 0.01 to 0.05 seconds are routinely used.

Other machine settings also influence radiograph quality. Selection of a smaller focal spot setting, if available, will result in sharper edge definition. Increases in the focal spot-to-film distance will positively affect detail; however, the mAs (milliamperes seconds) or the kVp (kilovolt peak) also must increase proportionately. A compromise focal spot-to-film distance of 40 inches (100 cm) is often used.

Scatter radiation adversely affects the detail of radiographs. This is particularly true when high-detail or mammography screens are used. Close collimation of the primary beam around the areas of interest is important to decrease scatter. Birds are routinely positioned with the film cassette on the tabletop. This decreases the object-to-film distance and maximizes detail. Grids are useful to decrease scatter radiation when the thickness of the object being imaged is greater than 4 inches (10 cm); however, few birds are thicker than this so grids are rarely used.

Film-screen combinations contribute significantly to image quality and exposure settings. A “faster” film will have larger silver halide crystals. The larger size of these

crystals makes them more likely to be exposed to x-rays or light, thus they require a lower exposure to produce an image. However, the image will be less sharp than the same image made on a “slower” film with smaller crystals and a higher exposure. Intensifying screens are generally made of rare-earth crystals that fluoresce when struck by x-rays. Mammography cassettes<sup>a</sup> and film<sup>b</sup> offer an excellent combination for high-detail radiographs. The initial cost of the screens is higher, but used screens are often available at discounted prices through human imaging centers. Mammography film is more expensive than standard radiographic film. Mammography cassettes have screens on only one side and mammography film is single-sided emulsion. Proper loading of the cassettes is essential. The dark side of the film faces the dark side of the cassette and the light side faces the light side (Figs 25.1, 25.2). Most automatic processors can routinely develop these films, though their non-standard size may create problems in some models. Mammography film is often still damp after the drying cycle as programmed into most automatic processors. Care should be taken to avoid damage to the developed film and to provide for additional drying time. It also is important to realize that mammography cassettes require a higher exposure setting than typical double-screened cassettes (Table 25.1). Non-screen film such as dental radiography film also provides excellent detail and requires higher exposure settings.

**Table 25.1** | Technique Chart Used for Psittacines in the Author’s Practice Using Mammography Cassettes<sup>a</sup> and Film<sup>b</sup>

Species	mA	Time (in sec)	kVp (kilovolt peak)
Budgerigar	300	1/10	40
Cockatiel	300	1/10	41-42
Pionus/mini macaw	300	1/10	43
Amazon/African grey	300	1/10	45
Large cockatoo/macaw	300	1/10	48-50



**Fig 25.3** | Routine positioning of an anesthetized bird for the ventrodorsal projection.



**Fig 25.4** | Routine positioning of an anesthetized bird for the laterolateral projection.

## POSITIONING

The principles of positioning the avian patient for radiography are the same as for other species. At least two views, 90° to each other, are suggested. Positioning may be maintained by taping the patient directly to the cassette or to a radiolucent Plexiglas board. Masking tape is usually sufficient in the chemically immobilized patient and has the advantage of not pulling out feathers when it is removed.

The basic views of the body are the laterolateral and the ventrodorsal (Figs 25.3, 25.4). When assessing positioning for the laterolateral view, the two femoral heads should overlies one another, the legs should be pulled caudally, the sternum should be parallel to the film and the wings should be secured dorsally. In the ventrodorsal view, the legs should be pulled caudally. Wings are stretched and secured laterally, and the sternum should directly overlies the vertebral column.

Standard views of the wing are the ventrodorsal (positioned as for the body) and the caudocranial view. The legs are evaluated with routine orthogonal lateral and anterior/posterior views.

Skull radiography is challenging due to overlap of multiple structures, and their complex relationships. In order to optimize interpretation of these films, lateral, ventrodorsal and oblique projections are suggested.<sup>15</sup>

Radiography of the skull is indicated for evaluation of bony structures, including identification of fractures, luxations, hyper- and hypocalcemia, and carcinoma.<sup>8</sup> Sinuses and soft tissue structures may be visualized, but changes

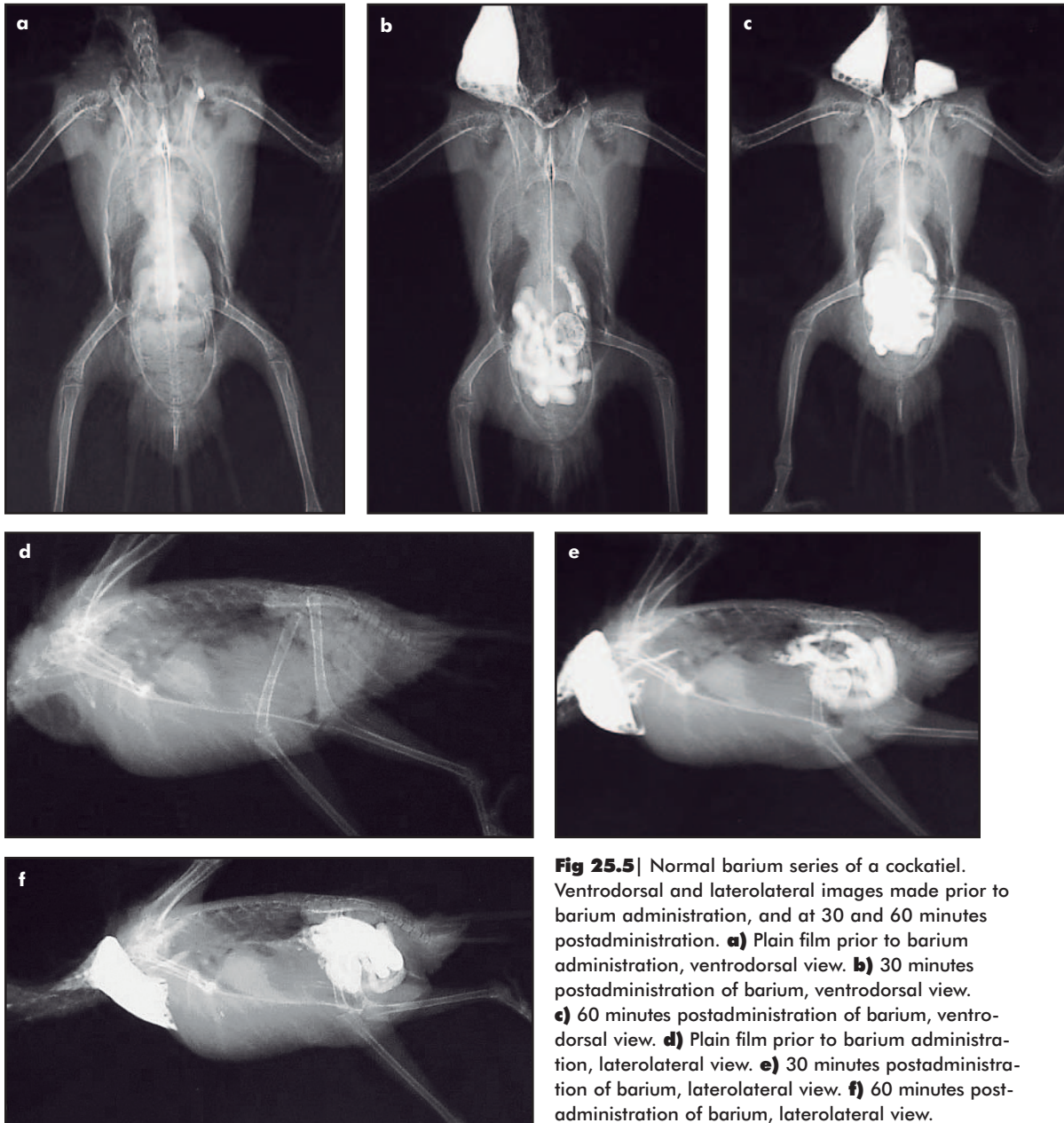
in these structures tend to be visible only in advanced stages of disease. Magnetic resonance imaging (MRI) is a more sensitive tool for evaluation of these structures.<sup>16</sup>

The standard oblique views are left 75° ventral-right dorsal and right 75° ventral-left dorsal. The lateral view is obtained with the bird positioned in lateral recumbency with the neck extended. Foam wedges are used to support the skull such that the sagittal plane of the skull is parallel to the film. For the ventrodorsal view, the patient is placed in dorsal recumbency with the neck hyperextended such that the hard palate is parallel to the cassette. Tape is used to secure the beak to the cassette. Additional views may be required on a case-by-case basis. Endotracheal tubes may interfere with interpretation of skull views, especially the ventrodorsal. If pathology is suspected, the endotracheal tube can be removed and an additional radiograph obtained.

## GASTROINTESTINAL CONTRAST STUDIES

Contrast studies of the upper and lower gastrointestinal (GI) tract are often indicated based on suspicion of space-occupying masses, ulceration, abnormalities in size or shape of coelomic organs, GI foreign bodies, alterations in GI motility or body wall abnormalities (Figs 25.5a-f).

Thirty percent weight to volume barium sulfate suspension is the most commonly used contrast medium. Approximately 25 ml/kg given by gavage tube into the crop is the suggested guideline. Iohexol<sup>c</sup> (240 mg iodine/ml) diluted 1:1 with tap water also may be used



**Fig 25.5** | Normal barium series of a cockatiel. Ventrodorsal and laterolateral images made prior to barium administration, and at 30 and 60 minutes postadministration. **a)** Plain film prior to barium administration, ventrodorsal view. **b)** 30 minutes postadministration of barium, ventrodorsal view. **c)** 60 minutes postadministration of barium, ventrodorsal view. **d)** Plain film prior to barium administration, laterolateral view. **e)** 30 minutes postadministration of barium, laterolateral view. **f)** 60 minutes postadministration of barium, laterolateral view.

at 25 to 30 ml/kg.<sup>4</sup>

A preliminary study comparing GI transit time of psittacines restrained manually to those chemically restrained with isoflurane revealed no significant differences between the two groups.<sup>11</sup> Regardless of the type of restraint used, great care should be taken to avoid contrast aspiration, especially in the early stages of the study when the crop is distended. Precautions include avoiding external pressure on the crop, maintaining the head in a slightly elevated position and intubation of anesthetized birds.

The use of iohexol<sup>c</sup> results in significantly decreased GI transit time.<sup>4</sup> The crop-to-cloaca transit time of barium is

approximately 3 hours, compared to approximately 1 hour with iohexol.<sup>c</sup> If barium is used, films are made at 5, 30, 60, 90, 120 and 180 minutes or possibly longer. A slightly different schedule of 1, 3, 15, 30, 60 and possibly 120 minutes is recommended if iohexol<sup>c</sup> is used. Iohexol<sup>c</sup> also eliminates concerns of contrast material residue if endoscopy or surgery is indicated. If perforation is suspected or possible, iodinated contrast should be used.

Retrograde or cloacally administered barium may be useful in detection of cloacal or colonic abnormalities such as ulcerations or masses. Caution should be used to avoid barium entering the oviduct or ureters.

# Ultrasound

Ultrasonography uses the transmission and reflection of sound waves to produce an image. Organ visualization in the avian patient is limited when compared to mammalian species, as the ultrasound waves cannot penetrate the gas-filled air sac system. However, there are several applications for use of ultrasonography in the avian patient.

Due to the small size of most birds and the limited windows of accessibility, the ultrasound transducer must have a small contact area or footprint. Sector transducers, producing a wedge-shaped image, are appropriate as they tend to be smaller than linear transducers and allow good maneuverability. Their disadvantage is a smaller field of view compared to a linear transducer. This is of minimal consequence when dealing with the small avian patient. A transducer frequency of 7.5 MHz or higher is recommended.<sup>9</sup>

There are three acoustic windows to the coelomic viscera of the avian patient: (1) the cranioventral approach, on midline just caudal to the sternum; (2) the caudovertral approach, between the pubic bones; and (3) the lateral approach, in the flank area directly behind the last rib on each side. Based on the size of the bird and the size of the transducer, not all of these windows may be accessible in each patient.

While not always necessary, patients ideally should be fasted for 2 to 4 hours prior to examination. Food and gas within the gastrointestinal tract may impede visualization of other organs. Birds are restrained in dorsal recumbency, with the head and cranial coelom elevated with a 30° foam wedge to assist in visualization. Feathers are either parted or plucked and wetted with a small amount of isopropyl alcohol. Acoustic coupling gel is applied to the skin to provide adequate contact between the transducer and the skin. In the non-pathologic state, liver, heart and active gonads (usually the ovaries) are distinguishable. Spleen, normal kidneys and inactive gonads are difficult to identify.<sup>9</sup>

The indications for ultrasound include investigation of superficial soft tissue masses, hepatomegaly, cardiac disease, renomegaly, disorders of the reproductive tract and identification of ascites.

Hepatomegaly is commonly diagnosed with conventional radiography. The normal liver should not extend caudal to the sternum and has a characteristic coarse, homogeneous echotexture similar to the mammalian liver.<sup>9</sup> Hepatic disease can be focal or diffuse. The abnormal areas may be sampled by fine needle aspiration (FNA) or biopsy for definitive diagnosis. General anes-

thesia is recommended for both procedures.

Ultrasound-guided hepatic FNA is accomplished using a 22-gauge, 1-inch needle with a 6-inch extension set. A study comparing FNA sampling techniques found that collecting multiple parenchymal samples with the needle under 0.5 ml of suction produced the most high quality hepatic cells with the least hemodilution<sup>14</sup>. In this study of 27 normal Amazon parrots, no morbidity or mortality was associated with hepatic FNA. Percutaneous ultrasound-guided hepatic biopsies may be obtained using a 20-gauge Trucut needle. The depth of the biopsy will vary with the size of the bird.

Echocardiography in the avian patient is in its early stages.<sup>9</sup> The heart is usually visualized cranial to the liver via the cranioventral acoustic window. Standardized imaging planes and chamber sizes have yet to be established. Endocarditis, pericardial effusion, valvular insufficiency and cardiomyopathies may be diagnosed using mammalian criteria as a guide (see Chapter 12, Evaluating and Treating the Cardiovascular System).

The normal kidneys are not visible during ultrasound examination due to their anatomic position within bony depressions of the pelvis and the surrounding abdominal air sacs. Nephromegaly may be detected if the kidneys extend beyond normal landmarks, as described in radiographs discussed above, and can be characterized as focal or diffuse. Ultrasound-guided renal biopsy has not been reported.

Inactive gonads are not generally identified on ultrasonographic examination. Active or enlarged gonadal tissue can be evaluated with ultrasound. In the male, testes enlarged due to seasonal, neoplastic or inflammatory conditions may be identified. A study of the normal sonographic appearance of the reproductive tract of 52 hens of various species identified 17 of 34 (50%) active ovaries, all in hens greater than 70 g body weight.<sup>9</sup> Active ovaries were characterized by the presence of follicles in various states of development. Follicles are initially round with indistinct anechoic or hypoechoic inner structure. As development advances, the more echogenic yolk is visualized. The ovarian parenchyma, identified between follicles, has higher echogenicity and a non-homogeneous appearance due to the presence of rudimentary follicles. As ova progress through the magnum, they exhibit distinct separation of echogenic yolk surrounded by anechoic albumen. The hyperechoic shell is added in the uterus and is easily distinguishable. The shell prevents further examination of the inner structures of the egg. Cysts of the ovary are visualized as clearly defined, rounded, anechoic structures within the parenchyma. Cysts may occur singly or in multiples.

Ultrasonographic examination is particularly valuable in cases of suspected egg binding. Thin-shelled, non-shelled, malformed and fully shelled eggs can be identified. Mineralized eggs are visible as round to oval structures of varying echogenicities resembling onion layers. They are surrounded by anechoic to hypoechoic fluid. Concurrent salpingitis should be suspected when oviduct walls appear thickened. The inflammatory exudate in the lumen of the oviduct may be anechoic to hypoechoic (see Chapter 18, Evaluating and Treating the Reproductive System).

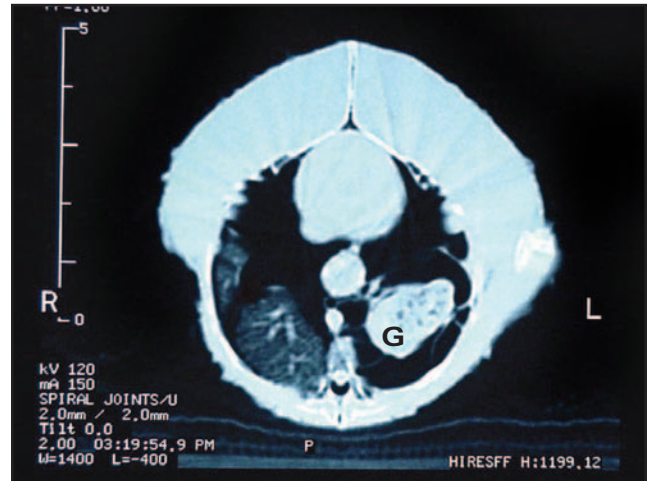
## Computed Tomography

Computed tomography (CT) is a cross-sectional imaging modality that uses x-rays to create a digital image or slice (Fig 25.6), that can be reformatted into additional planes of view.<sup>2</sup> Image densities are similar to conventional radiographs. The cross-sectional image eliminates overlying structures so objects of interest are more accurately visualized. CT is best suited for evaluation of bone and air-filled structures. Soft tissue resolution is inferior to MRI (see below). Reports of the use of CT include examination of the skull, sinuses and the lower respiratory tract.<sup>1,6,8,10</sup> Machines vary in acquisition time and width of slice. Typically, the study can be performed in less than 10 minutes. General anesthesia is required for the study.

## Magnetic Resonance Imaging

A review of the physics of magnetic resonance imaging (MRI) is beyond the scope of this chapter. Simplistically, a strong external magnetic force is used to align certain atoms within the body about a desired axis. The field is then turned off and the unit senses energy released as atoms return to their resting state.<sup>2</sup> The image produced is cross-sectional.

MRI is particularly useful for imaging soft tissue structures including the brain, spinal cord, coelomic organs and the upper respiratory tract. This MRI modality has been evaluated in the diagnosis and management of chronic sinusitis in psittacines.<sup>16,17</sup> In contrast to conventional skull radiography, where identification of disease was limited to osseous changes or changes in pneumatization, MRI was successful in the identification of caseous plugs, granulomas, a mucocele and a polyp.<sup>16</sup> The accurate localization of these lesions within the sinuses permitted the planning of an optimal surgical approach and drain placement for treatment.



**Fig 25.6** | Computed tomography image of a transverse slice through the coelom of an Amazon parrot at the level of the lungs. The right lung is normal. The normal architecture of the left lung is replaced by a cystic mass that was diagnosed as a foreign-body-associated granuloma (G) on histopathologic examination. The heart, keel and normal pectoral musculature are visible toward the top of the image.

Advances in the technology of MRI have decreased the time required for image acquisition, though general anesthesia is routinely required. MRI studies usually take a longer period of time to perform than CT studies. The decreasing cost and increasing availability of this imaging modality will increase its usefulness in avian diagnostics.

## Myelography

Techniques for myelography in avian patients have been described.<sup>5</sup> Indications include evaluation of the spinal cord for compressive, traumatic or space-occupying lesions. MRI should be strongly considered as an alternative if feasible. In larger patients (1 kg and greater), a 25-gauge needle is placed at the thoraco-synsacral junction and 0.8 to 1.2 ml/kg of non-ionic iodinated contrast medium is injected into the subarachnoid space (see Chapter 17, Evaluating and Treating the Nervous System).

## Excretory Urography

Excretory urography (EU) is indicated for identification of renal mass lesions, ureteral obstruction and abnormalities in renal excretion. The use of sodium diatrizoate (680 mg I/kg), iohalamate sodium (800 mg I/kg), and meglumine diatrizoate (800 mg I/kg) has been reported without adverse effects.<sup>12</sup> Contrast agents are warmed to body temperature prior to intravenous administration, and radiographs are made at 1, 2, 5, 10 and 20 minutes. The technique has been described in

further detail.<sup>12</sup> The absence of a renal pelvis and physiologic variations in avian renal function limit the usefulness of this procedure in birds. See Chapter 16, *Evaluating and Treating the Kidneys* for further considerations and alternate contrast agent doses.

## References and Suggested Reading

- Antinoff N, et al: Correlation between computed tomography and anatomy of the psittacine sinus. *Proc Assoc Avian Vet*, 1996, pp 367-368.
- Berry CR: Physical principles of computed tomography and magnetic resonance imaging. In Thrall DE (ed): *Textbook of Veterinary Diagnostic Radiology* 4<sup>th</sup> ed. Philadelphia, WB Saunders Co, 2002, pp 28-35.
- Drost WT: Basic ultrasound physics. In Thrall DE (ed): *Textbook of Veterinary Diagnostic Radiology* 4<sup>th</sup> ed. Philadelphia, WB Saunders Co, 2002, pp 20-28.
- Ernst SE, et al: Comparison of iohexol and barium sulfate as gastrointestinal contrast media in mid-sized psittacine birds. *J Avian Med Surg* 12(1):16-20, 1998.
- Harr KE, et al: A myelographic technique for avian species. *Vet Radiol Ultrasound* 38(3):187-192, 1997.
- Jenkins JR: Use of computed tomography (CT) in pet bird practice. *Proc Assoc Avian Vet*, 1991, pp 276-279.
- Krautwald-Junghanns ME: Avian imaging. *Proc 4<sup>th</sup> Europ Coll Avian Medi Surg*, 2001, pp 343-353.
- Krautwald-Junghanns ME, Kostka VM, Dorsch B: Comparative studies on the diagnostic value of conventional radiography and computed tomography in evaluating the heads of psittacine and raptorial birds. *J Avian Med Surg* 12(3):149-157, 1998.
- Krautwald-Junghanns ME, Riedel U, Neumann W: Diagnostic use of ultrasonography in birds. *Proc Assoc Avian Vet*, 1991, pp 269-275.
- Krautwald-Junghanns ME, Schumacher F, Tellhelm B: Evaluation of the lower respiratory tract in psittacines using radiology and computed tomography. *Vet Radiol Ultrasound* 34(3):382-390, 1993.
- Lennox AM, Crosta L, Buerkle M: The effects of isoflurane anesthesia on gastrointestinal transit time. *Proc Assoc Avian Vet*, 2002.
- McMillan MC: Imaging techniques. In Ritchie BW, Harrison GJ, Harrison LR (eds): *Avian Medicine: Principles and Practice*. Delray Beach, FL, HBD International Inc, 1999, pp 246-326.
- Newell SM: Radiology for the avian patient/Y2K and beyond. *Proc Assoc Avian Vet*, 2000, pp 421-424.
- Nordberg C, et al: Ultrasound examination and guided fine-needle aspiration of the liver in Amazon parrots (*Amazona* species). *J Avian Med Surg* 14(3):180-184, 2000.
- Paul-Murphy JR, et al: Psittacine skull radiography: Anatomy, Radiographic Technic and Patient Application. *Vet Radiol* 31(4):218-224, 1990.
- Pye GW, et al: Magnetic resonance imaging in psittacine birds with chronic sinusitis. *J Avian Med Surg* 14(4):243-256, 2000.
- Romagnano A, et al: Magnetic resonance imaging of the avian brain and abdominal cavity. *Proc Assoc Avian Vet*, 1995, pp 307-309.
- Rosenthal K, et al: Ultrasonographic findings in 30 cases of avian coelomic disease. *Proc Assoc Avian Vet*, 1995, p 1.
- Rosenthal K, et al: Computerized tomography in 10 cases of intracranial disease. *Proc Assoc Avian Vet*, 1995, p 1.
- Thrall DE, Widmer WR: Radiation physics, radiation protection, and darkroom theory. In Thrall DE (ed): *Textbook of Veterinary Diagnostic Radiology* 4<sup>th</sup> ed. Philadelphia, WB Saunders Co, 2002, pp 1-19.

## Products Mentioned in the Text

- Microvision Detail mammography cassette, Agfa, Greenville, SC, USA
- Microvision Ci, Agfa, Greenville, SC, USA
- Iohexol, Omnipaque®, Amersham Health, 1-800-654-0118

