

In general, the techniques of evaluating the avian eye are similar to those used in mammals. However, the small size of the eye in companion birds and the striated sphincter muscle of the avian iris necessitate modified procedures to visualize the posterior segment of the eye.

Each ophthalmologist has a particular pattern for ophthalmic examination. The key to effective evaluation is to develop a logical, consistent use of the same pattern of examination for each eye.

Before a bird is agitated by restraint, the eyes should be evaluated from a distance, noting whether the bird will fixate on moving objects, whether both pupils are the same size and whether there are any obvious abnormalities in the periorbital area (Figure 26.1). Vision can be difficult to evaluate because birds can feel slight air movements created by an approaching hand. The detailed examination requires adequate restraint, and a darkened room will calm the bird and improve the illumination provided by a focal light source.

Many disease processes affect the external eye and periorbita. Ocular discharge, conjunctival hyperemia or periorbital swelling can be an indication of a primary ocular disorder or may occur secondary to sinusitis or facial dermatitis (see Chapter 24). Some larger Psittaciformes may inflate a portion of their periorbital sinus as an aggressive gesture, creating a transient swelling in the periorbital region (Color 26.7). This swelling should not be mistaken for periorbital disease. Collapse of the anterior chamber may occur in an otherwise normal eye following a period of head restraint or lateral recumbency during anesthesia. Normal anterior chamber depth is rapidly regained.

Examination of the anterior segment can be performed with a bright pen light, a binocular loupe, an operating microscope, an ophthalmoscope set on +20 diopters or, ideally, a slit lamp (Figure 26.2). Key features to evaluate are the clarity of the cornea, the aqueous, the lens and the color and vascularization of the iris. Aqueous flare, as seen in uveitis, can be detected by looking for scattering of a slit light beam that is passing through the anterior chamber (Colors 26.25, 26.26). Pupillary light reflexes can be determined, but because the avian iris is under conscious control, rapid changes in pupil diameter according to

CHAPTER

26

OPHTHALMOLOGY

David Williams



FIG 26.1 Normal periocular area in a Grey-cheeked Parakeet. The eye should be open with a bright, shiny appearance. The lid margins should be evenly colored, dry and symmetrically shaped.

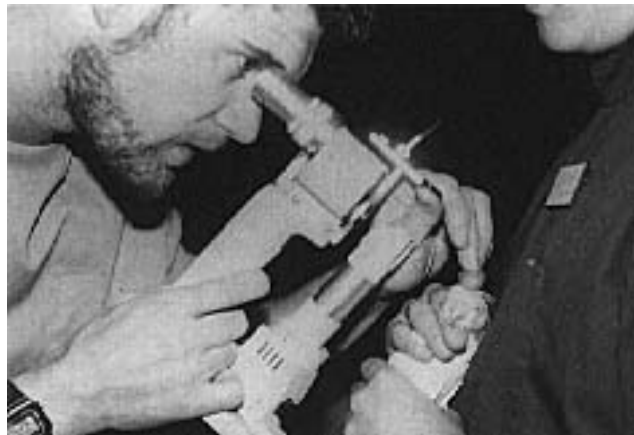

FIG 26.2 A slit lamp is ideal for examining the anterior segment of the avian eye. The lamp can also be used to facilitate evaluation of oral and dermatologic lesions (courtesy of David Williams).

the degree of alertness of the animal can make evaluation difficult.

Retinal examination is difficult in many birds because of the small size of the eye and the lack of response of the avian iris to conventional parasympathomimetic mydriatics. Mydriasis can be accomplished by intracemeral injection of d-tubocurarine or by the frequent use of a freshly prepared topical 3 mg/ml solution of crystalline d-tubocurarine in 0.025% benzilonium chloride over a fifteen-minute period.^{5,56} A more practical approach may be the topical use of commercially available neuromuscular blocking agents commonly used for intravenous in-

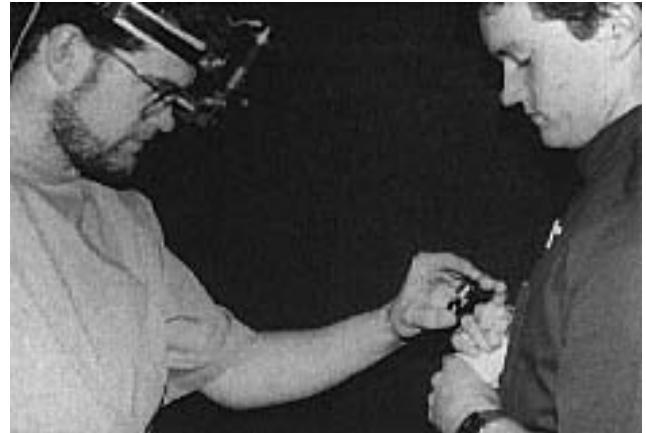

FIG 26.3 Indirect ophthalmoscopy in a cockatiel to evaluate the fundus. A 28 diopter lens is particularly useful but results in an inverted image that requires some practice to interpret (courtesy of David Williams).

jections. The most useful regime in raptors has been found to be vecuronium bromide solution (4 mg/ml) topically every five minutes for fifteen minutes (see Chapter 18).⁵³

With or without mydriasis, the easiest way to view the fundus is to start with the direct ophthalmoscope at the +20 dioptre setting, and with the instrument close to the bird's eye, change the dioptre setting gradually back to zero. This will bring the pleated pecten into view. It is then possible to focus on the avascular retina at the posterior of the eye. An indirect ophthalmoscope is excellent (Figure 26.3), although an expensive binocular all-pupil model is needed if adequate mydriasis is not achieved. A 28 or 40 dioptre lens is useful to obtain a good field of view in the small avian eye. A 90 dioptre lens used with a slit-lamp provides excellent visualization of a large area of the fundus.

■ Ancillary Tests for Evaluation of the Eye

Further testing can be used to confirm or refute the presence of suspicious lesions detected by gross observation. Corneal ulcerations can be detected by staining with fluorescein dye. The Schirmer Tear Tests can be used on birds, although normal data for psittacine birds have not been published. Conventional 6 mm-wide Schirmer tear test filter paper strips have been found to be difficult to insert in the lower conjunctival sac of the smaller Psittaciformes; thus trimming these to 4 mm is more useful. This also gives a higher reading of wetted strip length than the 6 mm-wide filter strips, with which the Schirmer tear test results are rarely over 3 in clinically normal

birds. To date, Schirmer tear test readings have been found to be 8 ± 1.5 mm in the larger Psittaciformes such as the African Grey Parrot, and 4.5 ± 1 mm in smaller species such as lorries and conures.

The difference in tear production between species is presumably related to the size of the orbit and lacrimal gland tissue. These interspecies differences make it difficult to provide standard normal data for all Psittaciformes. With unilateral problems, comparison between the affected and the unaffected eye may be useful. A normal bird of the same species, ideally an enclosure mate, can also be used for comparative purposes.

Tonometry is possible in birds, but little normal data has been published. The simple indentation Schiotz tonometer cannot be used in smaller birds because of its large footplate, which covers the cornea and sclera in all but the largest avian species. However, the portable Tonopen applanation tonometer is ideal for use in birds. One study indicates that this instrument provided reproducible readings in birds with corneal diameters over 9 mm. Some readings in birds with corneal diameters as small as 5 mm were reliable.⁴⁰ This tonometric examination of 275 birds (39 species) showed intraocular pressures in normal eyes of between 9.2 and 16.3 mmHg. Among 14 species of psittacine birds, values were found to be 14.4 ± 4.2 mmHg with a sample size of 74 birds.

Avian periorbital and external eye disease is frequently associated with infectious agents. A consistent technique for sample collection should be used to increase the validity of the sample. The best diagnostic bacteriologic samples can be obtained by inserting a sterile swab moistened in transport medium into the upper conjunctival fornix and rubbing it from side to side two or three times. The upper fornix is the preferred site for collecting culture samples because there is less contamination from environmental organisms than in the lower fornix. Conjunctival scrapings can be stained with a modified Wright's stain for general cytology. A Giemsa stain can be used to detect chlamydial elementary bodies (see Chapters 10, 34).¹⁴

Anatomy of the Eye

An understanding of the anatomy of the avian eye (Figures 26.4-26.7) and how it differs from the mammalian eye is vital when differentiating between the normal and abnormal.^{24,46,52,68,77}

As an overview, the avian eyelids are mobile, the lower more so than the upper. The meibomian glands are absent, but a lacrimal gland (varying in size between species) is present, inferior and lateral to the globe. The Harderian gland acts as a second lacrimal gland at the base of the nictitating membrane (Figure 26.5). The nictitating membrane actively moves over the cornea during blinking and in the menace response (Color 26.1). It has an unusual muscular arrangement; it is drawn across the eye by the pyramidal muscle originating in the posterior sclera and loops over the optic nerve through a sling formed by the bursalis muscle (quadratus muscle.) Inferior and superior nasolacrimal puncta at the medial canthus drain lacrimal secretions into the nasal cavity (Color 26.2).

The orbit is open, but, because the globe occupies the vast majority of the space, the rectus and oblique muscles are not well developed, and torsional movements of the globe are limited in many species to between two and five degrees. A key point in the anatomy of the avian orbit is the close proximity of the tightly packed orbit with the infraorbital diverticulum of the infraorbital sinus (Figure 26.5). Sinusitis and enlargement of this diverticulum will

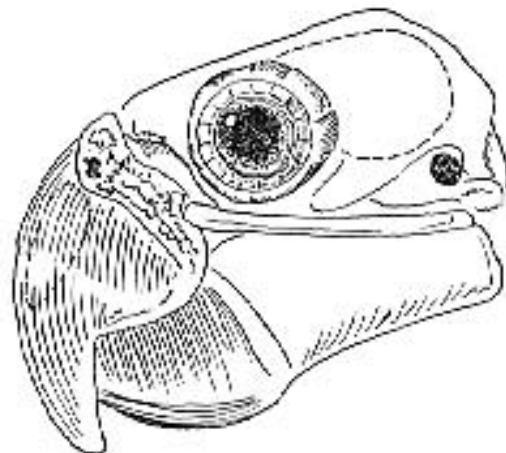


FIG 26.4 Relative size of the globe to the skull.

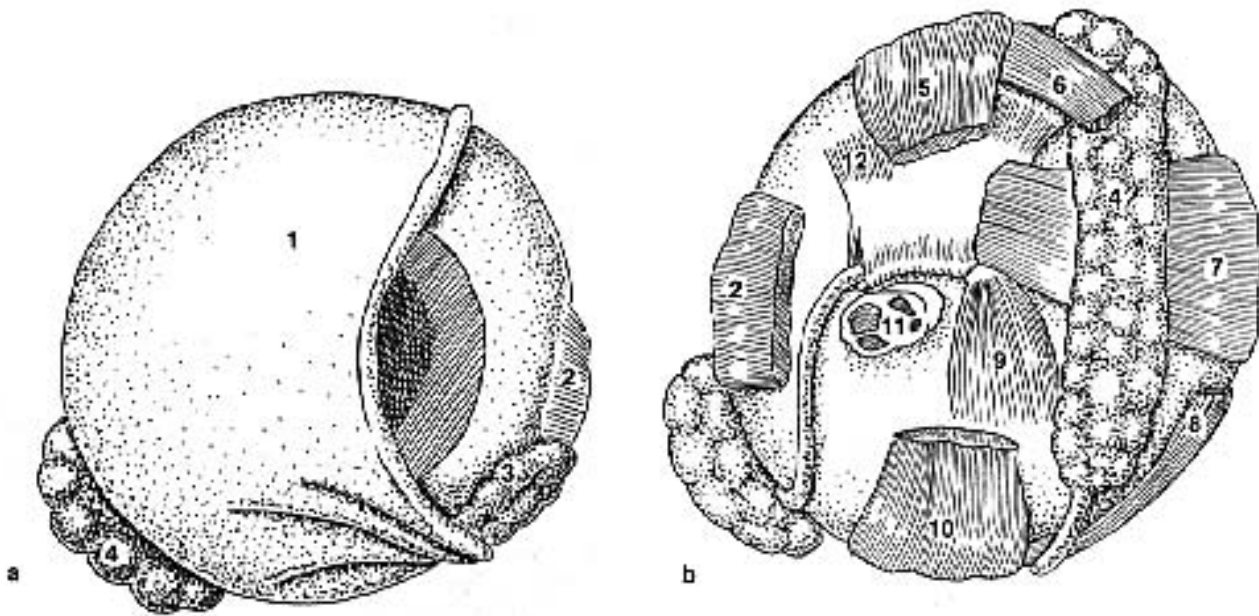


FIG 26.5 a) Anterior and b) Posterior view of the avian globe. 1) Nictitating membrane 2) M. lateral rectus 3) lacrimal gland 4) gland of nictitating membrane 5) M. dorsal rectus 6) M. dorsal oblique 7) M. medial rectus 8) M. ventral oblique 9) M. pyramidalis 10) M. ventral rectus 11) optic nerve and 12) M. quadratus (modified from Martin⁴⁶).

therefore lead to periorbital or orbital compression and signs of periorbital swelling, conjunctivitis and sometimes intraocular disease (Color 26.16).

In most birds, including Psittaciformes, the globe is antero-posteriorly flattened, with a hemispherical posterior segment. It is rounded in some diurnal birds and tubular in owls (Figure 26.6). The sclera immediately posterior to the cornea contains scleral ossicles, and through its full circumference, the sclera has a support of hyaline cartilage (Figure 26.7). The avian cornea is similar to that of mammals except that it is considerably thinner, and unlike mammals, it has a Bowman's layer. The thickness of the cornea varies depending on the size of the bird. The anterior segment is relatively shallow compared with the posterior segment, with some anatomic differences noted between species. Owls have an unusually deep anterior chamber (Color 26.21).

The iris is thin and contains striated dilator and constrictor muscles. Varying chromatophores create the different iris colors noted with age, gender and species of some birds. In some white cockatoo species, for example, the iris is dark brown in the adult male

and reddish pink in the adult female. Immature cockatoos of both genders have black irides. In the Moluccan Cockatoo, however, the male has a black iris and the female has a dark brown iris, and in most black cockatoo species and in the Goffin's Cockatoo, there is no gender difference in eye color. Young Blue and Gold Macaws have a dark iris that lightens in the first two to three years and then turns yellow as the bird ages. African Grey Parrots have dark muddy-grey irides as young birds, which turn yellowish-grey and then silver as they mature.

Pupillary light reflexes do occur in birds but their interpretation is complicated by the fact that voluntary constriction and dilation of the pupil is possible, even in the absence of retinal stimulation. Clinically, the complete separation of the optic nerves prevents the elicitation of a consensual pupillary light reflex. The iridocorneal angle is well developed in all birds and drains the aqueous fluid, as in mammals. The lens is soft and is almost spherical in nocturnal birds, or has a flattened anterior face in diurnal species including companion birds. An annular pad lies under the lens capsule in the equatorial region, and can be separated from the center of the lens during cataract surgery.

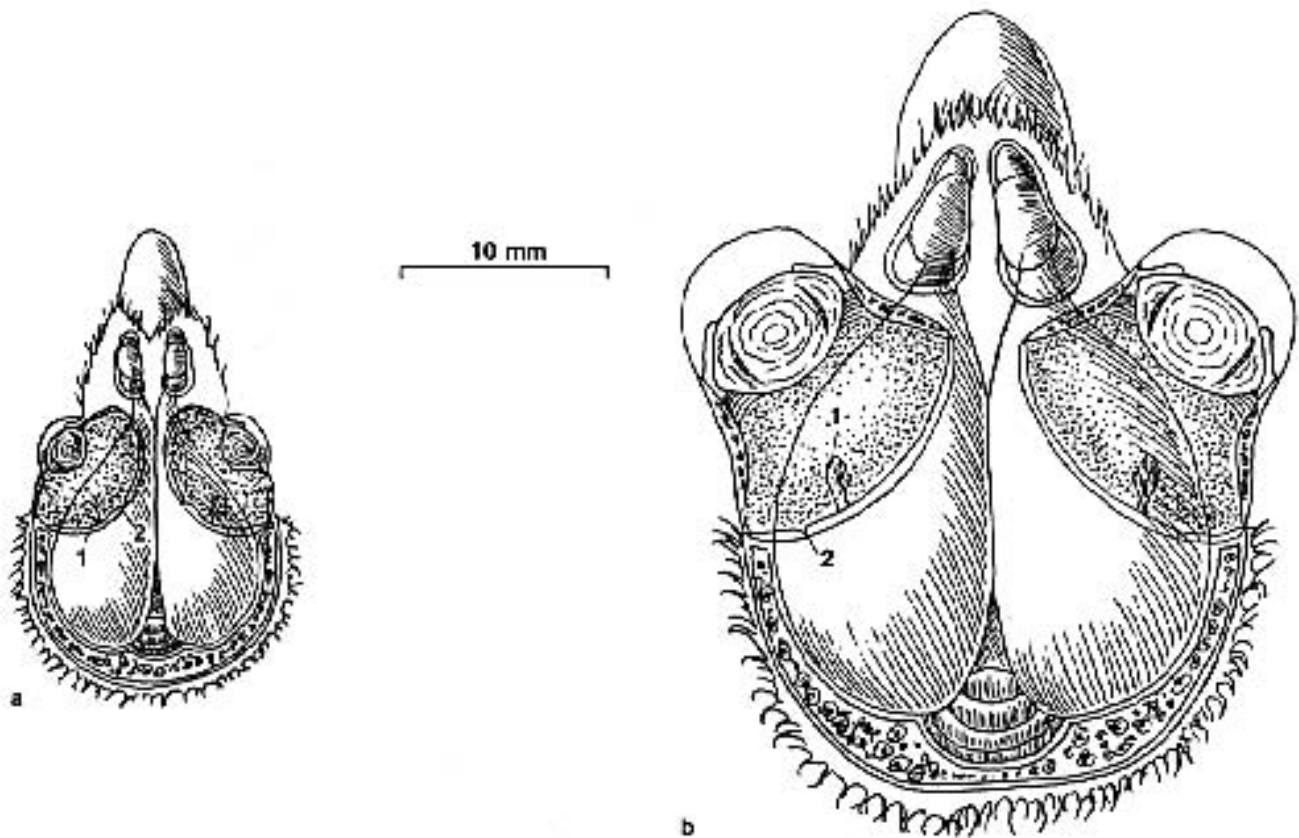


FIG 26.6 a) In diurnal birds, like this chickadee and most companion birds, the lens has a flattened anterior surface, whereas b) in nocturnal birds, like this Great Horned Owl, the lens is almost spherical. 1) pecten 2) fovea (modified from Martin⁴⁶)

The color of the fundus varies considerably among species; however, all species have a pecten, a comb-like black or brown projection of choroidal tissue that extends into the vitreous (Color 26.35). Recent work has shown that small, regular torsional movements of the eye sweep the pecten through the relatively fluid vitreous. Blood vessels in the pecten disperse a serum filtrate that extends to the peripheral retina.⁶² The pecten is thought to provide oxygen and nutrients to the inner portion of the retina. Most species, including Psittaciformes and Passeriformes, have indistinct foveae. Many raptors have one and some diurnal raptors and hummingbirds have two foveae. Macaws have a particularly distinct foveal area that can be evaluated fundoscopically. It is suggested that in bi-foveate birds, one fovea serves for near vision and the other accommodates long-range vision. Birds can distinguish colors and in most cases have excellent visual acuity. Because a bird's sight is so important behaviorally, it is critical that ophthalmologic problems are accurately diagnosed and rapidly resolved.

Ophthalmic Disorders

Lids and Periorbita

One of the most common ocular presentations in large psittacine birds is periorbital disease secondary to upper respiratory infection, particularly chronic rhinitis and sinusitis (Figure 26.8) (see Chapter 22). As stated above, the close proximity of the infraorbital sinus to the orbit predisposes it to physical displacement when the sinus diverticulum is enlarged. In some cases, cellulitis or abscessation occur from spread of organisms from the sinus cavity. Antibiotics alone are rarely efficacious in these cases; flushing the sinus and, in some cases, more aggressive surgical debridement is required (see Chapter 41).

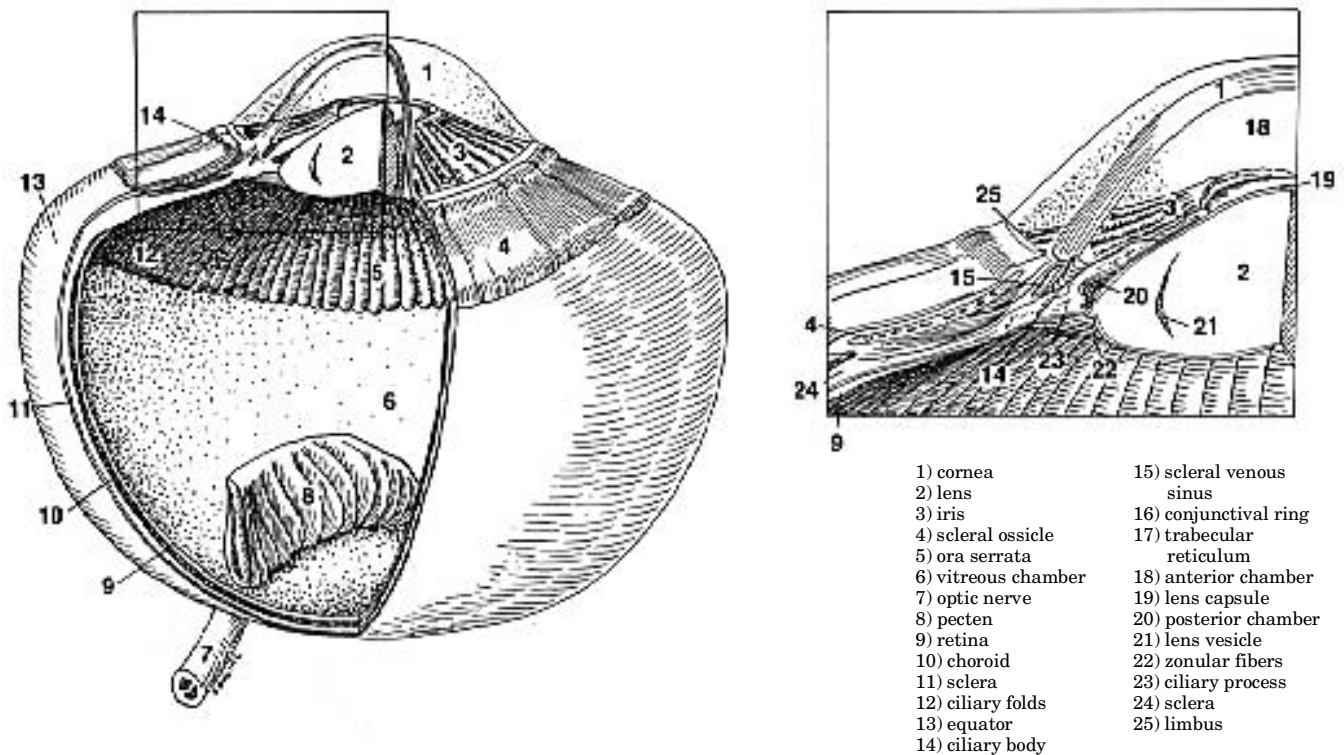


FIG 26.7 Three-dimensional representation of the avian eye; enlarged view of the interior of the eye.

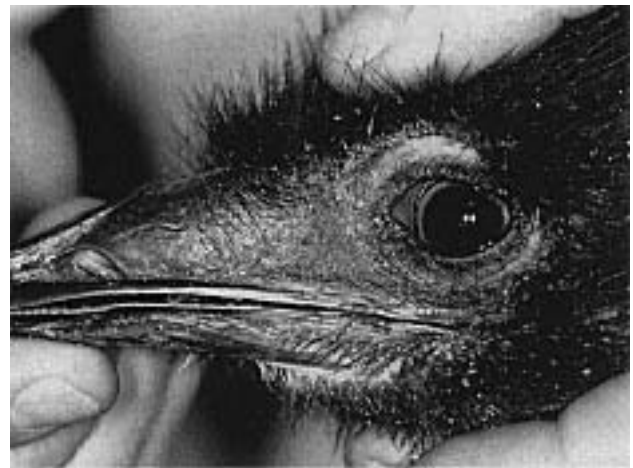

FIG 26.8 An emu (left) was presented with a history of chronic sinusitis. A serous to mucoid oculonasal discharge was noted on physical examination. The sinus was retracted into the skull (“sunken sinus syndrome”). This condition has been most frequently reported in macaws but may also occur with sinusitis in other avian species. Antibiotics were curative (see Chapter 22). A normal emu (right) is shown for comparison (courtesy of Tom Tully).

Poxvirus

Avian poxvirus may cause lesions in or around the eyes in a number of species (see Chapter 32). The initial changes include a mild, predominantly unilateral blepharitis with eyelid edema and serous discharge starting about 10 to 14 days post-infection

(Color 26.8). As the disease progresses, ulcerative lesions on the lid margins and at the medial or lateral canthus develop; these can become secondarily infected, giving rise to a mucopurulent discharge and transient ankyloblepharon (Color 26.9). The lids be-

come sealed shut with a caseous plug or with dry crusty scabs, which fall off within two weeks.⁵⁰

Clinical lesions provide a tentative diagnosis. An infection can be confirmed through histopathologic identification of eosinophilic intracytoplasmic inclusion bodies (Bollinger bodies) in scabs or scrapings of periocular ulcers.^{27,34}

Poxvirus infections may cause keratitis and, less commonly, anterior uveitis. The keratitis can be mild with corneal clouding or severe with ulceration that progresses to panophthalmitis and rupture of the globe. Keratitis may lead to permanent corneal lid scarring. Cicatricial changes in the lid margins can lead to entropion, ankyloblepharon or deformities of the lid edge, resulting in keratitis from corneal abrasion or environmental exposure. These patients may need corrective surgery (lid retraction) or can be placed on life-long therapy with ocular lubricants.

Many affected psittacine birds, particularly Amazons, pionus parrots and mynah birds, have residual problems that cause more important pathology than the primary ocular and periocular lesions. In one study, 46% of the Amazon parrots and pionus parrots with poxvirus had post-infection ocular abnormalities.³⁵ Eyelid and corneal lesions are most severe if poxvirus lesions are secondarily infected with bacteria or fungus. Treatment of poxvirus lesions should include topical antibiotic ophthalmic ointments to reduce the incidence of these sequelae. Systemic antibiotics may also be required in severely affected birds. Early eye lesions should be flushed with dilute antiseptic solutions. Once scabs have formed they should not be removed. It may be beneficial to soften scabs with hot or cold compresses soaked in nonirritating baby shampoo. It has been reported that prophylactic vitamin A supplementation of exposed birds decreases the severity of infection³⁶ (see Chapter 18). The importance of subclinical hypovitaminosis A in the progression of the disease has not been determined.

Hypovitaminosis A

Hypovitaminosis A is less prevalent today than a decade ago; however, it may still be seen as a complicating factor in ocular diseases. Xerophthalmia is said to be the classic sign of hypovitaminosis A in many avian species, but the most common ocular change in psittacine birds is mild periorbital and conjunctival swelling with some discharge (Color 26.14). These signs can be subtle. Hypovitaminosis A

should be considered in cases of unexplained ocular discharge or swelling.

Nasal discharge, sneezing, crusted nares, dry oral membranes and palatine and choanal abscesses are highly suggestive of primary hypovitaminosis A, particularly in Amazon parrots. Response to injectable vitamin A or oral beta carotene supplementation suggests the involvement of a deficiency in the disease process.^{42,63}

Lovebird Eye Disease

A severe and often fatal systemic disease with periocular lesions as the presenting sign has been reported in lovebirds. Generalized depression is accompanied by blepharitis and serous ocular discharge, followed by hyperemia and edema of the periorbital area with a mucopurulent ocular discharge. Affected birds are often attacked by enclosure mates and usually die within a few days of the onset of ocular signs. The disease is most commonly seen in the Peach-faced mutations, and it is in these birds that the lesions are most severe.

No definitive isolation of an infectious agent has been achieved, but an adenovirus-like particle has been demonstrated in renal tissue by electron microscopy. Conjunctival inclusions have been found in some affected birds.^{32,36} The histologic lesions reported in one case included proliferative inflammatory reaction of the subconjunctival tissue with lymphoid cell infiltration and concurrent atrophic changes in conjunctival epithelium. Conjunctival edema with minimal cellular infiltrates were characteristic in other cases. The disease occurs most frequently immediately after shipping or introduction into a new aviary, suggesting that stress may be involved in initiating pathologic changes. Symptomatic therapy that includes isolation of affected birds in a stress-free environment and administration of antibiotics has been suggested.

CLINICAL APPLICATIONS

- Sinusitis frequently causes ocular disease because of the close proximity of the infraorbital sinuses and the globe.
- Hypovitaminosis A may cause mild periorbital swelling.
- Lacrimal sac masses present as mobile swellings anteroventral to the medial canthus.
- Pupillary light reflexes are difficult to interpret because birds can voluntarily constrict and dilate the pupil.

■ Ophthalmology

Color 26.1

A three-month-old Blue and Gold Macaw was presented with a two-week history of serous nasal discharge. Note the accumulation of debris on the feathers of the face. The nictitating membrane, which moves over the cornea during blinking and in the menace response, is normal. This bird's rhinitis was caused by exposure to cigarette smoke.

Color 26.2

An Umbrella Cockatoo was presented with a two-month history of unilateral discharge. Note the moist, discolored feathers on the face. The nasolacrimal duct in this bird was occluded and was opened by repeated flushing with warm, sterile saline.

Color 26.3

Depression and hyperemia of the face and eyelids in a gallinaceous bird with sinusitis and pneumonia.

Color 26.4

Periocular dermatitis in an Amazon parrot from southern Florida. These lesions, frequently encountered in birds in outdoor aviaries, are believed to be caused by biting insects.

Color 26.5

a) Gross proliferative lesions caused by *Knemidokoptes* sp. infection in a budgeri-

gar. b) *Knemidocoptes* spp. are most frequently associated with beak and cere lesions but can also cause lesions in the periorbital tissues (courtesy of the Unit for Continuing Veterinary Education in London and John E. Cooper).

Color 26.6

A mature cockatiel was presented for diarrhea and weight loss of five days' duration. The bird had partial paresis of the eyelid, mild conjunctivitis and was unable to bite. Partially hulled seeds were common in the bottom of the enclosure. *Giardia* spp. were detected in a fecal smear. The bird responded to treatment with metronidazole and vitamin E.

Color 26.7

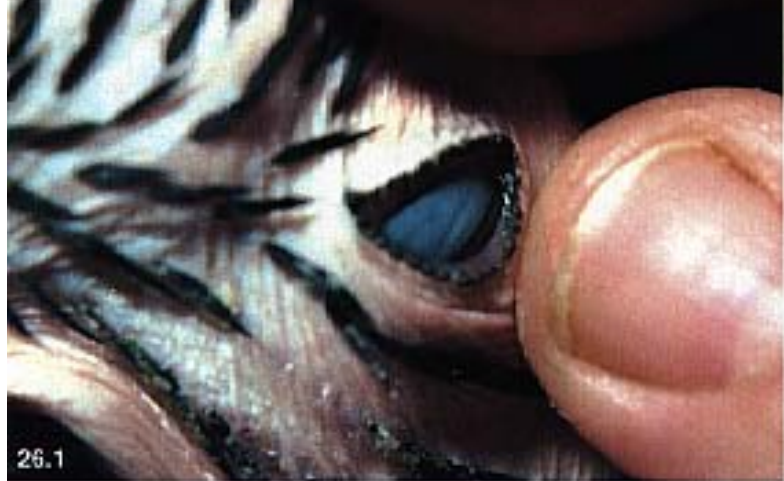An Amazon parrot with a transient periorbital sinus inflation. This inflation is believed to be secondary to stressful events and is not indicative of a pathologic problem.

Color 26.8

Scarring of the palpebral margin secondary to a poxvirus infection (courtesy of David Williams).

Color 26.9

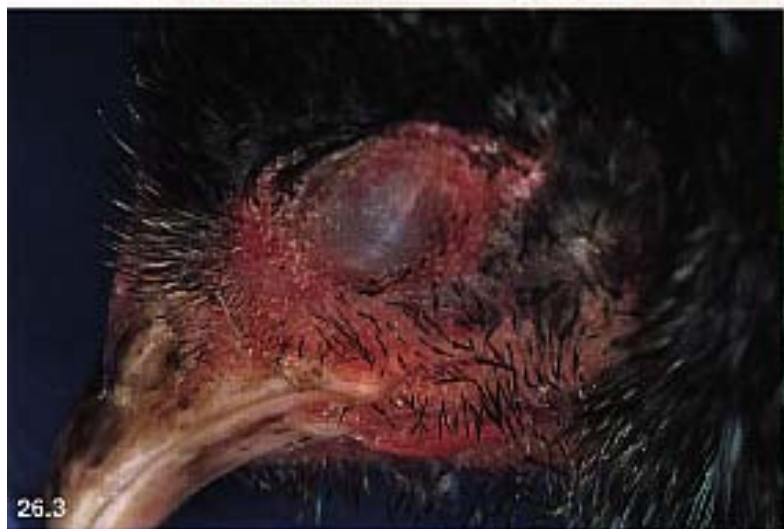Poxvirus in a canary (courtesy of Louise Bauck).



26.1



26.2



26.3



26.4



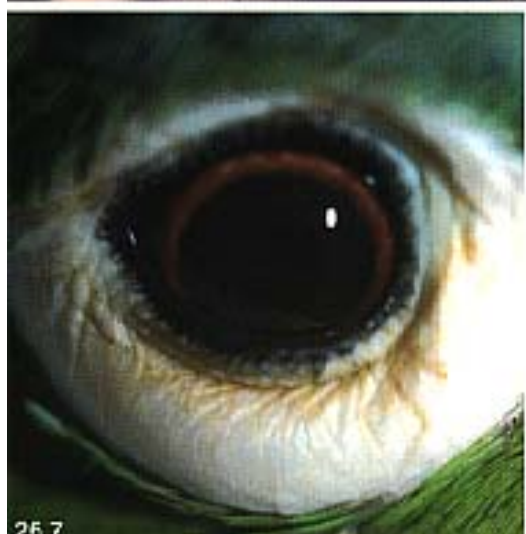26.5a



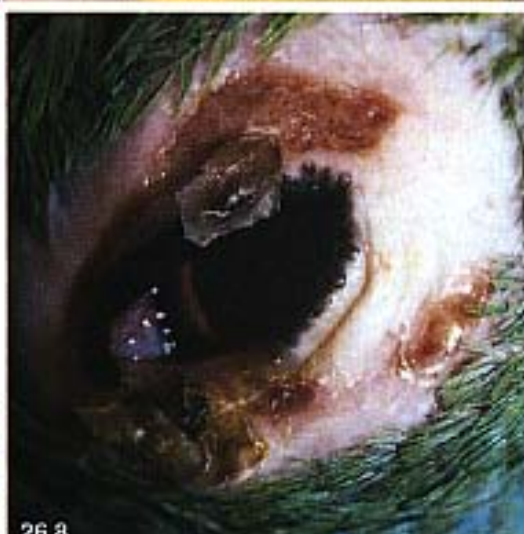b



26.5



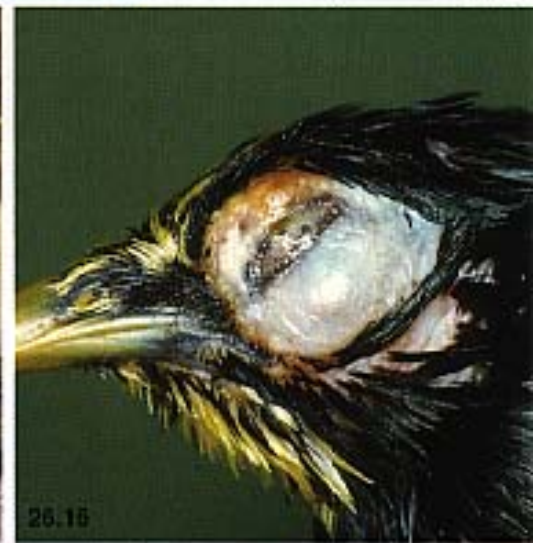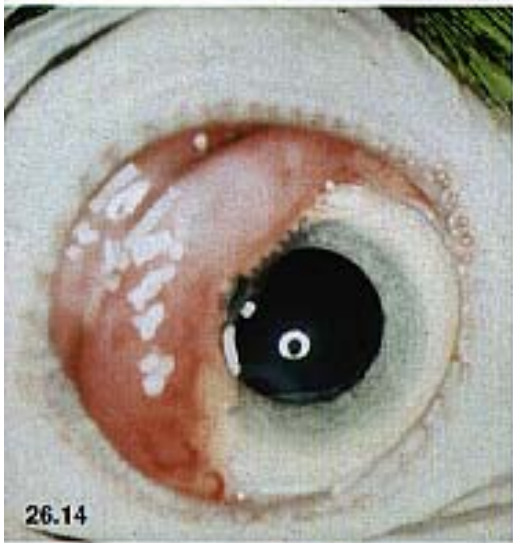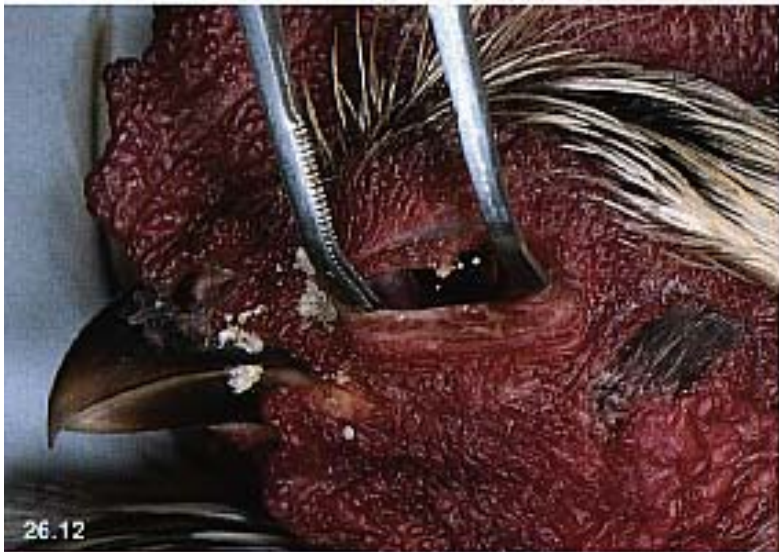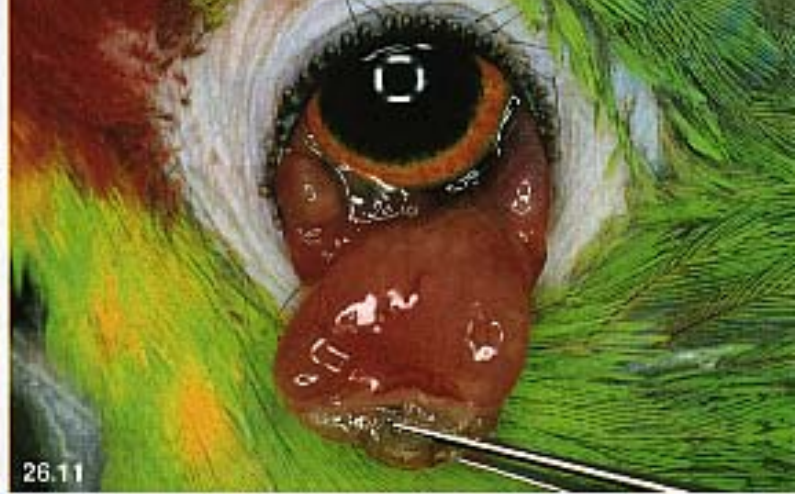26.7



26.8



26.9



■ Ophthalmology

Color 26.10

A budgerigar with conjunctivitis, epiphora and chemosis of seven to ten days' duration. The etiology is unknown but the clinical presentation is similar to that described with conjunctivitis in cockatiels. In this case, topical application of enrofloxacin resolved the chemosis within four days (courtesy of R. Korbelt).

Color 26.11

Subconjunctival granuloma in an Amazon parrot. Chemotic conjunctivitis in this bird was not ameliorated with topical or systemic tetracycline and enrofloxacin treatment. Ziehl-Neelsen staining of the granulomatous conjunctival tissue revealed *Mycobacterium* spp. The conjunctiva was surgically removed (courtesy of R. Korbelt).

Color 26.12

An adult *Arcuna* was presented with a two-week history of progressive depression and weight loss. The bird had a bilateral, serous ocular discharge and preferred to keep the eyes shut. *Thelazia* spp. were noted on physical examination. The bulk of the nematodes was removed with copious flushing (LRS), and the bird was successfully treated with topical ivermectin.

Color 26.13

Conjunctivitis in an ostrich caused by flukes (*Philophthalmus* sp.). This bird was housed in an area that contained a water-fowl pond. Most infected birds are housed in low-lying, damp areas.

Color 26.14

Hypovitaminosis A in psittacine birds can cause dysplastic lacrimal gland lesions (courtesy of David Williams).

Color 26.15

Cockatiel conjunctivitis frequently responds to therapy with tetracyclines (courtesy of Louise Bauck).

Color 26.16

Infraorbital sinusitis in a 2.5-year-old Indian Hill Mynah. Surgical removal of caseous masses followed by treatment with enrofloxacin and vitamin A successfully resolved the lesion (courtesy of R. Korbelt).

Color 26.17

A four-year-old female budgerigar was presented with a three-week history of progressive ocular swelling and ataxia. The bird died shortly after presentation. Abscesses present in the infraorbital sinuses also involved portions of the calvarium.

Color 26.18

An eight-year-old African Grey Parrot was presented with a twelve-day history of progressive upper respiratory disease. This was the only companion bird in the household, but the bird had been boarded at a pet retailer two months before the onset of clinical signs. The client also had a flu-like disease. Chlamydia was detected by using a fecal antigen test, and the bird responded to doxycycline therapy. Note the rhinolith in the left naris.

Pasteurella spp. septicemia and gram-positive cocci have been associated with conjunctivitis in lovebirds. A poxvirus has been described in Masked and Peach-faced Lovebirds.⁴³

Periorbital and Orbital Abscesses

Periorbital disease with exophthalmos or strabismus is most likely to be caused by an abscess of the orbit or lacrimal gland. In some cases, periorbital neoplasia, either primary or secondary, can cause similar clinical changes. Periorbital abscesses generally result from chronic upper respiratory tract infection and sinusitis. They are most often seen in cockatiels, and can occur in any position in the orbit (Color 26.11). Early treatment of sinusitis reduces the incidence of these lesions. Surgical debridement of the abscesses with concomitant systemic antibiotics is the only effective treatment. Lacrimal sac abscesses must be differentiated from periorbital abscesses. The lacrimal sac masses present as mobile swellings at, or immediately anteroventral to, the medial canthus. Early dacryocystitis can sometimes be treated by expressing the inflammatory debris through the lacrimal punctum. More severe cases with firm, necrotic debris require cannulation and regular flushing with antibiotic solutions as dictated by bacteriologic culture and sensitivity. Surgical removal is not recommended because of the potential for scarring and long-term nasolacrimal drainage problems.

Periorbital Swelling of Neoplastic Origin

Any primary tumor arising in the periorbital or retrobulbar area can cause swelling with or without globe displacement.⁷ The periorbital area in birds appears to be a particularly common area for cutaneous manifestations of lymphoreticular neoplasia,¹³ represented clinically by periorbital swelling, globe displacement and feather loss.^{61,65} Exophthalmia or posteriorly directed strabismus may be noted.

Exophthalmos and globe deviation have been reported secondary to optic nerve glioma, orbital round cell sarcoma,^{2,26} and some advanced cases of pituitary chromophobe tumors in budgerigars.⁶⁹ Other less common causes of retrobulbar masses include *Mycobacterium* spp.,⁷⁹ *Aspergillus* spp. granulomas and disseminated cryptococcosis.²⁵

Hyperplastic Periocular Lesions

Proliferative and hyperplastic periorbital lesions are most commonly seen in budgerigars and canaries in response to *Knemidokoptes* spp. infections. Pitted or honeycombed, scaly and crusting lesions are easily noted in the periorbital area as well as on the beak,

vent and legs (Color 26.5). The periorbital lesions seldom cause problems even though they may be quite severe. Ivermectin can be used topically.

A potential differential diagnosis would include vitamin A deficiency, which can lead to periorbital epithelial hyperplasia and hyperkeratosis, but hypovitaminosis A lesions rarely achieve the size or proliferative extent seen with *knemidokoptes*. Periorbital papilloma-like virus infection in an African Grey Parrot resulted in hyperplastic parakeratotic epithelial proliferations.³³ Other periorbital papillomas have been described without viral isolation.

Other Periocular Dermatoses

Any dermatosis (eg, allergic, bacterial, fungal) can potentially affect the periorbital skin and occur in the periorbital region (Color 26.4). It should be noted that many periorbital dermal lesions appear to be exceptionally pruritic and that self-trauma can complicate the initial lesions.

Congenital Deformities

Although rare in birds, congenital eyelid abnormalities do occur and are a surgical challenge to correct. Partial agenesis of the upper eyelid, which was surgically corrected by creating a new lateral canthus at the point at which normal upper eyelid would be found, has been reported in a raptor.³⁷

Cryptophthalmos (fusion of the eyelid margins) has been reported in four cockatiels¹¹ in which dramatically reduced or absent palpebral fissures were described without other ocular abnormalities (Color 26.20). Reconstructive surgery was uniformly unsuccessful. Behaviorally, the birds appeared normal because some vision was possible through one or both eyes. Corneal dermoids have been reported in one goose, in which feathers grew out of the aberrant dermal tissue on the lateral aspect of the globe.¹² Microphthalmia and maldevelopment of ciliary body, retina and pecten, as well as retinal dysplasias and congenital cataracts have been described in raptors.¹⁰ The lacrimal ducts did not drain properly in an Umbrella Cockatoo with choanal atresia, resulting in a chronic ocular discharge (Figure 26.9). Ectropion with secondary exposure keratitis has been seen in cockatiels. This lesion can be resolved with a lateral canthoplasty (see Chapter 41).

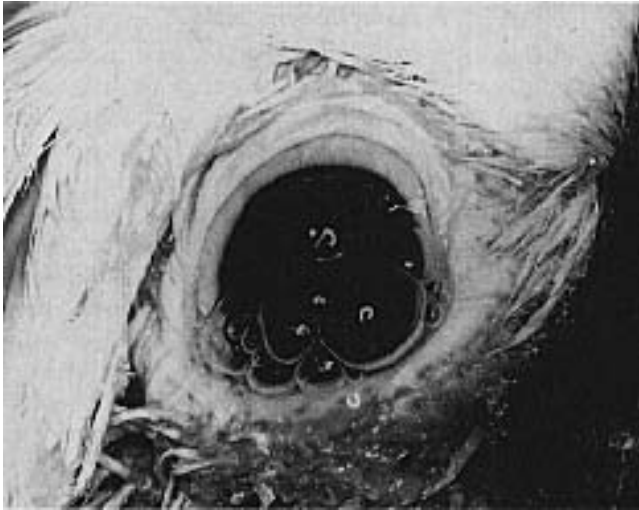


FIG 26.9 A mature Umbrella Cockatoo was presented with a life-long history of ocular nasal discharge. Physical examination indicated the lack of a choanal slit and an abnormally formed infundibular cleft, preventing normal lacrimal drainage. The periorbital tissue was moistened with a serous ocular and nasal discharge. Note the bubbles in the ocular fluids suggesting that air was exiting the lacrimal duct.

Conjunctiva

Differential Diagnosis of Conjunctivitis

Conjunctivitis can be classified clinically into three groups. The first are those caused by strictly local factors, such as localized conjunctival infection or foreign bodies. The second are those in which conjunctivitis is a manifestation of periorbital or orbital disease. These are mainly related to sinusitis (see Chapter 22). The third group are those in which conjunctival hyperemia is caused by a septicemia. Almost any organism causing systemic infection can result in conjunctivitis. A careful examination of the bird for upper respiratory disease is mandatory in determining the cause of ocular discharge or conjunctival hyperemia (Color 26.10). Exposure to cigarette smoke, chemical fumes and other aerosolized environmental toxins should always be considered in the differential diagnosis of conjunctivitis, with or without signs of upper respiratory disease.

Various infectious agents have been implicated in conjunctivitis, but mere isolation of a bacteria or protozoan does not imply that it is the cause of the disease. The conjunctival flora of captive exotic birds has been surveyed (Table 26.1).⁸⁰ Bacteria was isolated from the upper conjunctival fornix of 71% of the psittacine birds tested. *Staphylococcus* spp. or *Corynebacterium* spp. were isolated from 86% of the birds. Gram-negative bacteria were recovered from

14% and fungi, from 9% of these clinically normal birds. In another study, 41% of ocular samples were sterile and 50% of the isolates were gram-positive cocci.⁸²

TABLE 26.1 Avian Conjunctival Flora

Family	Gram + Isolates	Gram- Isolates	Fungal Isolates
Anseriformes	36/68 (56%)	30/68 (44%)	2/27 (11%)
Coraciiformes	3/3 (100%)	0/3 (0%)	0/2 (0%)
Falconiformes	17/18 (94%)	1/18 (6%)	4/11 (36%)
Piciformes	6/7 (86%)	1/7 (14%)	1/5 (20%)
Psittaciformes	44/51 (86%)	7/51 (14%)	5/55 (9%)
Rheiformes	6/18 (33%)	12/18 (67%)	2/5 (40%)
Falconiformes	17/18 (94%)	1/18 (6%)	4/11 (36%)

Adapted from Wolf DE, et al: J Am Vet Med Assoc 183:1232-1233, 1983.

The incidence of gram-positive, gram-negative and fungal organisms was determined in a group of 117 birds by swabbing the conjunctiva. The birds sampled were clinically asymptomatic and were housed in zoos or pet shops. *Staphylococcus* spp. or *Corynebacterium* spp. were recovered from 85 of 97 birds in which bacterial organisms were recovered. *Chlamydia* spp. was not identified by cytologic evaluation of conjunctival scrapings in any of the birds.

In one study of domestic ducks, *E. coli* was isolated from the eyes of a majority of clinically asymptomatic ducklings, suggesting that neonatal conjunctival flora are derived from intestinal flora (Color 26.24).¹⁶ The isolation of gram-negative bacteria from the eye or conjunctiva should be considered abnormal except in Anseriformes and Rheiformes, where gram-negative bacteria are considered autochthonous flora. *Haemophilus*-like bacteria have been reported to cause conjunctivitis in cockatiels.¹⁹

Chlamydia psittaci is a frequent cause of keratoconjunctivitis in Australian parakeets²³ and of conjunctivitis without other signs in pigeons and finches. In these cases, treatment with topical oxytetracycline is effective. Clinical chlamydiosis in Psittaciformes is generally associated with conjunctivitis, diarrhea and polyuria.

Mycoplasma spp. are important causes of conjunctivitis in pigeons and are suspected in many cases of conjunctivitis in cockatiels. Ocular discharge and conjunctivitis may be the only presenting signs. Other affected birds may develop rales, nasal discharge and sneezing. Unilateral conjunctivitis (one-eyed cold) in pigeons is frequently associated with mycoplasma but can also be caused by chlamydia or salmonella.

Cryptosporidial conjunctivitis has been described in pheasants⁶⁶ and ducks.⁴⁸ A case of blepharitis and conjunctivitis in a goose yielded *Actinobacillus suis*,⁴⁵ while *Mycobacterium avium* was isolated from a conjunctival granuloma in an ostrich.³¹

The presence of foreign bodies in the fornix, or behind the third eyelid, may be a cause of conjunctival irritation and should be suspected in cases of unilateral conjunctivitis that are not responsive to antibiotics. In one study, 7% of the free-ranging Red-shouldered Hawks had grass florets lodged behind the third eyelid.⁴⁹ In companion birds, millet seeds, seed husks and feathers have been associated with a foreign body conjunctivitis.

Cockatiel Conjunctivitis

Cockatiels are frequently presented with a conjunctivitis from which no infectious agent can be isolated. Clinical signs involve blepharitis and serous ocular discharge, progressing to conjunctival chemosis and inflammation with hyperemic conjunctiva protruding in front of the eye. These signs are seen much more frequently in white or albino mutations than in birds of normal gray color (Color 26.15).

The lesions are often associated with upper respiratory tract infection, and *Mycoplasma* spp. and *Chlamydia* spp. have been suggested as agents. Isolating mycoplasma requires specialized techniques, and diagnostic samples should be sent in specific media to qualified laboratories. Many cockatiels with conjunctivitis are not systemically positive for *Chlamydia* spp., shedding some doubt on the importance of this organism in the cockatiel syndrome.³

Treatment with topical antibiotics often ameliorates the signs but recurrences are common. Systemic tetracycline is often curative but should be combined with symptomatic treatment of the inflamed periorbital area. Antibiotic ophthalmic ointments may be used or the eyes can be sprayed with tylosin (1:10 dilution in sterile water) or lincomycin and spectinomycin. The problem seems to follow familial lines, suggesting that affected birds should not be used in breeding programs. In some cockatiels, the conjunctivitis is associated with partial lid paresis and reduced jaw tone (Color 26.6). Many of these birds have giardiasis and respond to treatment with metronidazole and vitamin E. A similar condition has been noted in budgerigars, and again, the etiologic agent has yet to be identified.⁴¹

Parasitic Conjunctivitis

A number of nematode and trematode parasites can occasionally cause conjunctival irritation in a wide variety of avian species (see Chapter 36). *Oxyspirura mansoni* is a nematode that has been associated with conjunctival irritation and pruritus in cockatoos, mynahs and other avian species. This nematode can enter the lacrimal duct and may cause transient epiphora if present in large numbers. Small numbers of nematodes can be manually removed or flushed out of the lower conjunctival sac. Heavy parasite burdens must be treated with a single topical dose of ivermectin.⁷⁴ This nematode has an indirect life cycle. Nematode eggs are passed through the nasolacrimal duct, swallowed and passed in the feces, where they are consumed by cockroaches (*Pycnoscellus* spp.). When a bird eats the cockroach, the mature nematode larvae escape into the crop, move up the esophagus and enter the nasolacrimal duct to reach the eye. Companion birds maintained in indoor environments are less likely to be infected. *Thelazia* spp. are reported to cause conjunctivitis in birds but are more common in mammals (Color 26.12).⁸

Trematode flukes of the genus *Philophthalmus* have been reported as a cause of conjunctivitis in many avian species (Color 26.13). The degree of irritation was sufficient in one group of ostriches to cause the birds to show persistent lacrimation, irritation and loss of condition. Repeated applications of topical carbamate powder eliminated the flukes.²⁹

Cornea

Treating Corneal Ulcers and Keratitis

Most corneal problems seen in Psittaciformes are epithelial erosions secondary to trauma or keratitis secondary to lid abnormalities. Fluorescein dye will stain denuded stroma indicating the presence of an ulcer. In subtle lesions such as Amazon punctate keratitis, an ultraviolet Wood's lamp can be used to augment the detection of fluorescein retention. Keratitis can be difficult to resolve, but, as a rule, topical antibiotics and corneal bandaging techniques provide a sterile environment and time for corneal epithelium to heal (Color 26.22). By extrapolation from other species, anticollagenases should be used in deep ulcers, especially in hotter climates, where corneal melting may be a cause of rupture of the globe. Acetylcysteine can be applied by spray every few hours without having to restrain the bird. A temporary tarsorrhaphy created by placing one or two horizontal mattress sutures of 4-0 or 6-0 nylon

provides a corneal “bandage.” This is preferable to a third eyelid flap because the muscular action moving the third eyelid can cause the suture to pull through. The use of a hydrated collagen shield to provide a medicated corneal bandage has not been reported in birds but may be useful in selected cases. Chronic corneal erosions may occur in older birds. To provide a suitable surface for reattachment of the epithelium, devitalized epithelium can be removed with a dry cotton-tipped applicator or by using a punctate or grid keratotomy.

Mynah Bird Keratitis

Corneal erosions may be noted secondary to capture and transport in many imported companion birds. The majority of these heal by corneal epithelial migration within 48 hours. Mynahs appear to be especially prone to handling-related keratitis. In one study, 96% of birds examined immediately after shipping were found to have corneal scratches.³⁶ Blepharospasm or some degree of conjunctival hyperemia is a characteristic finding. Many of these lesions regress spontaneously in a few weeks, but some may lead to corneal scarring and permanent opacity. Some birds develop a chronic keratoconjunctivitis with conjunctival masses, severe geographic corneal ulceration and corneal vascularization. Systemic aspergillosis is found in many chronically affected birds, suggesting an immunosuppressed condition. Acyclovir-responsive herpesvirus lesions have been suggested as complicating factors in some affected birds.

Amazon Punctate Keratitis

A transient keratitis with a characteristic subtle punctate appearance has been reported in Central American Amazon parrots. Lesions are bilateral, and the presenting signs are normally blepharospasm and a clear ocular discharge. The keratitis normally starts in the medial cornea. In 50% of the birds, lesions progress to cover the cornea but resolve generally within one to two weeks. The lesions are transiently fluorescein-positive. A small minority of birds develop more serious lesions with deep corneal ulceration and anterior uveitis, manifesting either as a flare and “muddiness” of the iris or as a more severe inflammation with fibrin clots and synechiae (Color 26.27). Some birds develop concomitant sinusitis. The use of topical antibiotics or antivirals has not been found to significantly alter the outcome of the disease.³⁶

Amazon parrots from northern South America have also been reported with a chronic keratitis. There are

fewer cases reported in this group of birds, but the incidence of long-term corneal scarring is higher.

Treatment of more severely affected birds, such as those with intraocular lesions, includes topical and systemic antibiotics. Topical corticosteroid to control intraocular inflammation can reduce the healing of concurrent corneal ulceration; topical non-steroidal anti-inflammatories such as indomethacin or flurbiprofen may be more appropriate in these cases.

Uvea

Uveitis in raptors is most commonly seen as a sequel to intraocular trauma⁵⁷ and is characterized by aqueous flare, hypopyon and fibrin clots in the anterior chamber, iridal hemorrhages or gross hyphema. The latter was reported to be the most common ophthalmologic finding in injured raptors in one survey.⁵⁸ Uveitis can occur following rupture of the crystalline lens^{1,54} or secondary to severe extraocular disease in conditions such as poxvirus infection. One case of bilateral intraocular inflammation with concomitant staphylococcus septicemia in a lovebird has been reported.⁶ Uveitis has been reported in psittacine birds with reovirus infection in which histopathologic changes suggested disseminated intravascular coagulopathy. Hypopyon and hemorrhage, sometimes with fixed dilated pupils (atypical for uveitis where miosis is more common), are characteristic ocular signs. Birds that recover may have synechiae (Color 26.28).¹⁷

Clinical signs of uveitis vary, reflecting the diversity of inflammatory states in the eye. Active inflammation may be mild, with increased levels of aqueous proteins causing a flare that reduces the clarity of iris detail and pupil margin. More severe cases may be characterized by accumulation of pus or hemorrhage in the anterior chamber. Subtle signs including a darkened iris or more obvious lesions including posterior synechiae or organized fibrin clots in the anterior chamber suggest a past episode of anterior segment inflammation. Glaucoma is seen secondary to traumatic uveitis in raptors,⁵⁸ and has been diagnosed without concurrent ocular disease in a canary. If the eye appears painful, enucleation or evisceration is the only treatment (Figure 26.10) (see Chapter 41).

Lens

Cataract and lens luxation can occur in birds. Both conditions can be treated surgically in suitable cases. Cataracts are seen relatively frequently³⁹ and have a

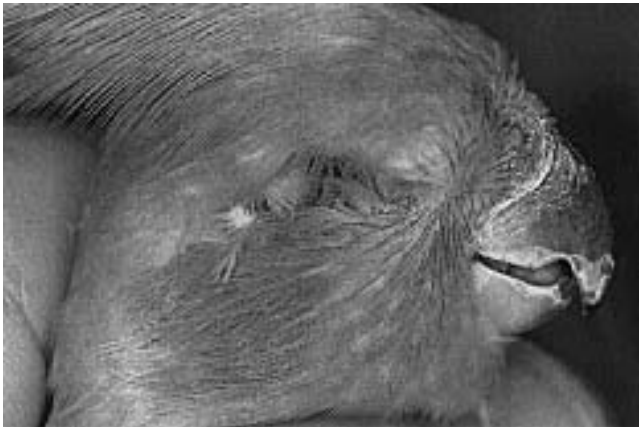

FIG 26.10 Although evisceration or enucleation can be disfiguring, these procedures may be life-saving in cases of severe infections or neoplasms.

wide variety of causes, although in the majority of cases the etiology is unknown. Senile cataracts have been described in macaws (Color 26.30).¹⁸

There is clear evidence for familial cataracts in Yorkshire and Norwich Canaries (Color 26.31).⁷² A fully penetrant autosomal recessive gene is responsible for the condition. In affected canaries, the cataracts were mature with lens-induced uveitis and posterior synechiae formation (Color 26.32). In one affected bird, lens resorption had taken place. Lens removal by the irrigation-aspiration technique was unsuccessful in these birds. Patients requiring cataract removal should be referred to a veterinary ophthalmologist.

Because of the small size of the avian eye, conventional extracapsular cataract extraction techniques are generally difficult. In small birds, soft lenses can be removed through a 26 ga needle. Phacoemulsification is the technique of choice for avian cataract removal in patients with eyes large enough to accommodate the phacoemulsification probe.³⁸ The extracapsular technique can be used in intumescent or resorbing cataracts where the lens material can be aspirated or flushed from the anterior chamber (Color 26.34).⁵⁵ An intracapsular technique has been used for removal of an anteriorly luxated lens in an owl.⁹ In eight aging macaws with senile cataracts, the lens was disrupted and removed with an irrigation aspiration technique, resulting in vision in 77% of the eyes.¹⁸ Post-operative treatment with 17% maxitrol was considered an indispensable part of the therapy. Topical medications, particularly steroids, must be applied cautiously to small birds to prevent intoxication.

Trauma in wild raptors is likely to be a frequent cause for lenticular opacification, and because other intraocular damage may be present, care should be taken in assessing the bird for cataract surgery (Color 26.34). Assessment should include full evaluation of the bird physically, neurologically and, of course, ophthalmoscopically. Ideally, ultrasonic evaluation of the posterior segment should be made to avoid operating on an eye with a concurrent retinal detachment. An electroretinogram gives useful data on retinal function and is suggested prior to surgery in some cases.³⁰

Miscellaneous Eye Conditions

Retinal Diseases

The difficulties in examining the posterior segment of the avian eye, especially in small companion birds, have delayed investigations into retinal disease in these species. The pioneering work of Casey Wood in the early part of this century on the normal avian fundus has not been surpassed even with the advances in ophthalmoscopic instrumentation and the growing interest in avian ophthalmology.⁸¹

Nevertheless, some reports of retinal disease in birds have found their way into the literature. Wood himself noted a high prevalence of posterior segment inflammatory lesions in captive raptors, and other authors have confirmed his findings.^{28,56,58} Lesions include pigmentary deposits on the otherwise unpigmented peripheral retina, focal scarring, pre-retinal membranes, vitreal opacities and gross inflammatory disease of the entire posterior segment (Color 26.35). Many of these lesions in free-ranging birds may be caused by trauma with hemorrhage that causes vitreal scarring and contraction. Posterior segment bleeding may result from choroidal vessels, a damaged ciliary body, or even in some cases, rupture of the pecten.

Toxoplasmosis has been suggested as a cause of retinal lesions in raptors (see Chapter 36). This report, however, was based on identifying seropositive birds in a population where the seroprevalence is unknown.²⁸ Toxoplasmosis was confirmed as a cause of retinitis and blindness in canaries. Toxoplasmosis was diagnosed in a group of canaries with crusty ocular lesions, white lesions in the vitreous humor and, in most cases, collapse of the globe. Several of the infected birds had neurologic signs characterized by circling and head tremors. High latex agglutination antibody titers to *T. gondii* were seen in five of the seven affected birds. Histologically, *T. gondii*

tachyzoites were demonstrated in the detached and intact retina, the lens and in exudate in the vitreous humor.⁷⁶

Retinal detachment can occur through trauma, but idiopathic bilateral detachments have been noted in pheasants unassociated with mechanical damage.⁶⁷ Retinal dysplasia has been diagnosed in raptors,^{21,60} and a retinal degeneration of unknown origin was reported in a parakeet.⁷⁵

Intraocular Tumors

Intraocular tumors are rare in birds. Malignant intraocular medulloepithelioma has been reported in two-year-old cockatiels in which, after enucleation for presumed bacterial panophthalmitis and orbital cellulitis, tumor masses grew rapidly in the orbit.⁷⁰ An intraocular adenocarcinoma has been reported in a budgerigar.²²

Neurophthalmology and Central Blindness

Blindness in birds may be caused by opacity of the visual media, retinal lesions or central neurologic disease. In cases where no obvious ocular cause of blindness can be observed, an electroretinogram can be used to differentiate between retinal or central lesions.⁴⁷

Causes of central blindness may include cataracts, neoplasia or encephalitis that may be localized or related to systemic disease. Heavy metal toxicities can result in blindness, but the visual changes are only one of a number of multifocal nervous signs. Space-occupying brain lesions, particularly pituitary

adenomas, can cause visual deficits from pressure being placed on the optic chiasm. One large survey of 50 chromophobe pituitary tumors reported central blindness in a number of birds with associated neurologic and endocrine signs.^{4,69}

Defects of cranial nerves III, IV and VI are somewhat difficult to appreciate in birds because there is relatively little torsional movement of the globe within the orbit. Horner's syndrome was suggested as a diagnosis in one bird in which a unilateral ptosis and mild miosis ameliorated by topical phenylephrine was noted.⁷⁸

- **Evaluating the Blind Bird:** Determining if visually defective birds are sound for release can be difficult. Some birds such as owls perform well with one eye, while releasing a one-eyed diurnal falcon to the wild might be considered unwise. Many companion birds can survive remarkably well with little or no vision, as has been noted with cockatiels with cryptophthalmos¹¹ and Bobwhite Quail with dense bilateral cataracts;⁴⁴ however, blindness can be very debilitating in some smaller Passeriformes where flying from perch to perch is behaviorally important.

Enucleation

Enucleation is frequently necessary in birds because of trauma, non-responsive inflammation or tumors. Enucleation is difficult because of the large size of the avian eye and the tight fit of the globe into the orbit. For further information on enucleation and other ophthalmic surgeries, see Chapter 41.

References and Suggested Reading

1. Anderson GA, Buyukmihci N: Phacoanaphylactic endophthalmitis in an owl. *Vet Pathol* 20:776-778, 1983.
2. Arnall L: Anaesthesia and surgery in cage and aviary birds. *Vet Rec* 73:188, 1961.
3. Bauck L: Three treatment protocols for cockatiel conjunctivitis. *Proc Assoc Avian Vet*, 1989, pp 92-96.
4. Bauck L: Pituitary neoplastic disease in budgerigars. *Proc 1st Intl Conf Zool & Avian Med, Hawaii*, 1987, pp 87-90.
5. Bellhorn RW: Laboratory animal ophthalmology. In Gelatt KN (ed): *Veterinary Ophthalmology*. Philadelphia, Lea & Febiger, 1981.
6. Bounous DI, Schaeffer DO, Roy A: Coagulase-negative *Staphylococcus* sp. septicemia in a lovebird. *J Am Vet Med Assoc* 195:1120-1121, 1989.
7. Brightman AH, Burke TJ: Eyelid tumor in a parakeet. *Mod Vet Pract* 59:683, 1978.
8. Brooks DE, Greiner EC, Walsh MT: Conjunctivitis caused by *Thelazia* sp. in a Senegal parrot. *J Am Vet Med Assoc* 183:1305-1306, 1983.
9. Brooks DE, Murphy CJ, Quesenbury KE, Walsh MT: Surgical correction of a luxated cataractous lens in a barred owl. *J Am Vet Med Assoc* 183:1298-1299, 1983.
10. Buyukmihci NC, Murphy CJ, Schulz T: Developmental ocular disease of raptors. *J Wildl Dis* 24:207-213, 1988.
11. Buyukmihci NC, et al: Eyelid malformation in four cockatiels. *J Am Vet Med Assoc* 196:1490-1492, 1990.
12. Busch TJ: Corneal dermoids in a goose. *New Zeal Vet J* 33:189-190, 1985.
13. Campbell TW: Neoplasia. In Harrison GJ, Harrison LR (eds): *Clinical Avian Medicine and Surgery*. Philadelphia, WB Saunders Co, 1986, p 507.
14. Campbell TW: Conjunctival cytology. In Campbell TW: *Avian Hematology and Cytology*. Ames, Iowa State University Press, 1988.
15. Cavill JP: Canary pox: Report of an outbreak in roller canaries (*Serinus canarius*). *Vet Rec* 76:463-465, 1964.
16. Chalmers WSK, Kewley DR: Bacterial flora of clinically normal conjunctivae in the domestic duckling. *Avian Pathol* 14:69-74, 1985.
17. Clubb SL: A multifactorial disease syndrome in African grey parrots (*Psittacus erithacus*) imported from Ghana. *Proc Intl Conf Avian Med*, 1984, pp 135-149.
18. Clubb SL, Karpinski L: Aging in macaws. *Proc Assoc Avian Vet*, 1992, p 85.
19. Devriese LA, Vianene N, Uyttebroek E, et al: Three cases of infection by *Haemophilus*-like bacteria in psittacines. *Avian Pathol* 17: 741-744, 1988.
20. Dorrestein GM, van der Hage MH: Aviculture and veterinary problems in lovebirds. *Proc 1st Intl Conf Zool & Avian Med, Hawaii*, 1987, pp 243-261.
21. Dukes TW, Fox GA: Blindness associated with retinal dysplasia in a prairie falcon (*Falco mexicanus*). *J Wildl Dis* 19:66-69, 1983.
22. Dukes TW, Petit JR: Avian ocular neoplasia - a description of spontaneously occurring cases. *Can J Comp Med* 47:33-36, 1983.
23. Emanuelson S, Carney J, Saito J: Avian pox in two black-masked coureurs. *J Am Vet Med Assoc* 173:1249-1250, 1978.
24. Evans HE: *Organa senoria*. In Baumeal JJ, et al (eds): *Nomina Anatomica Avium*. London and New York, Academic Press, 1979.
25. Fenwick B, Takeshita K, Wong A: A Moluccan cockatoo with disseminated cryptococcosis. *J Am Vet Med Assoc* 187:1218-1219, 1985.
26. Frost C: Experiences with pet budgerigars. *Vet Rec* 73:623, 1961.
27. Graham CL: Poxvirus infection in a spectacled Amazon parrot (*Amazona albifrons*). *Avian Dis* 22:340-343, 1978.
28. Greenwood AG, Barnett KC: The investigations of visual defects in raptors. In Cooper JE, Greenwood AG (eds): *Advances in the Study of Raptor Diseases*. Keighley, England, Chiron Publications, 1981.
29. Greve JH, Harrison GI: Conjunctivitis caused by eye flukes in captive-reared ostriches. *J Am Vet Med Assoc* 177:909-910, 1980.
30. Hacker DV, Shifrin M: Cataract extraction in a Mandarin duck. *J Am Anim Hosp Assoc* 24:679-682, 1988.
31. Hood HB: Eye pathology in an adult male ostrich (*Struthio camelus*). *Proc Am Assoc Zoo Vet*, 1978.

continued on page 694

■ Ophthalmology

Color 26.19

a,b) A mature Sun Conure was presented with an idiopathic occurrence of unilateral periocular hemorrhage. There was no known trauma and clinicopathologic findings were limited to mild anemia (PCV=35). The bird fully recovered and had no further problems.

Color 26.20

Cryptophthalmos with ankyloblepharon in a two-year-old male cockatiel. Surgery to restore a normal palpebral aperture was unsuccessful (courtesy of N. Buyukmihci).

Color 26.21

Snowy Owl with ulcer and corneal calcification caused by trauma. A punctate or grid keratotomy to restore normal epithelization would be indicated (courtesy of K.C. Barnett).

Color 26.22

Fungal keratopathy in an ostrich secondary to sand contamination of the eye. A third eyelid flap was attempted but the sutures failed because of the muscular action of the nictitating membrane. The bird responded to treatment with topical ketoconazole (courtesy of S. West).

Color 26.23

Corneal ulceration and globe collapse from unknown etiology in a seagull. The eye was enucleated.

Color 26.24

Conjunctivitis in a farm duck. Culture yielded *Acinetobacter* sp. and the lesions resolved using topical chloramphenicol ointment.

Color 26.25

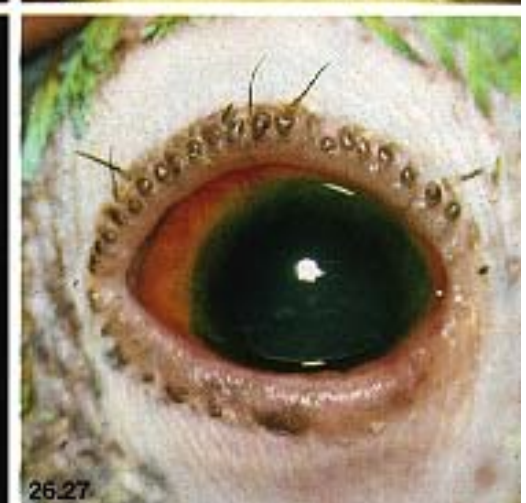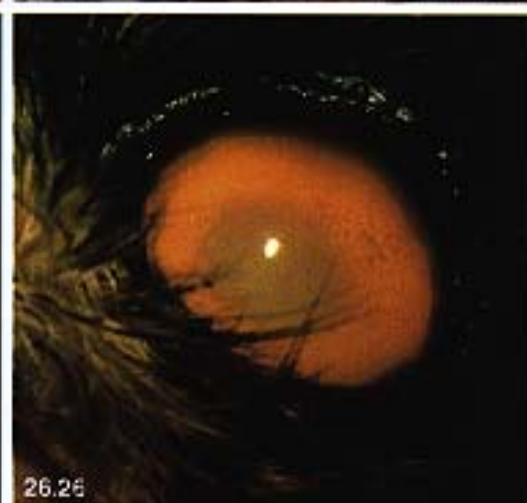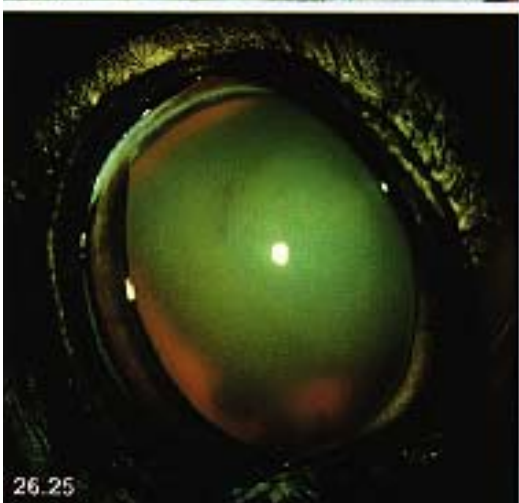
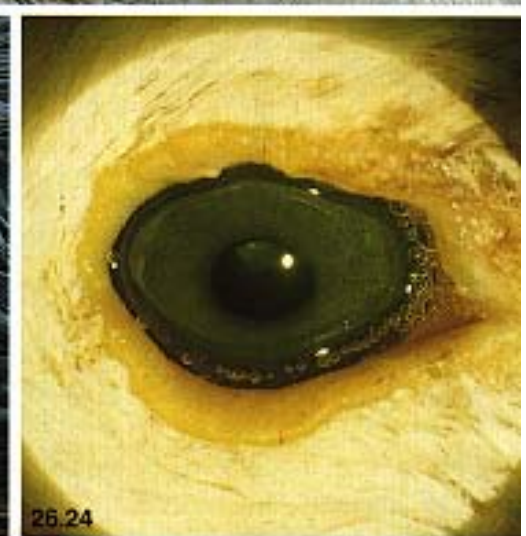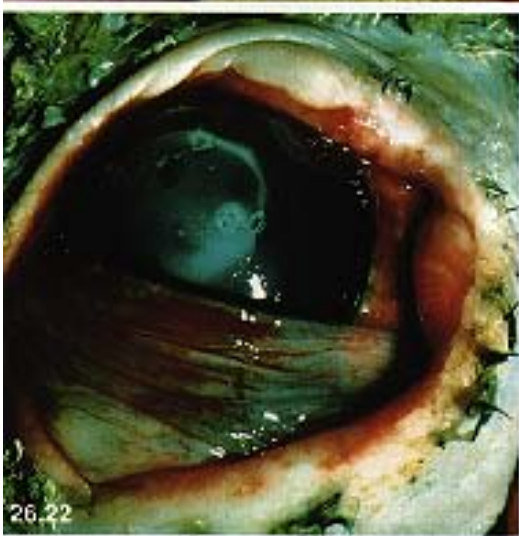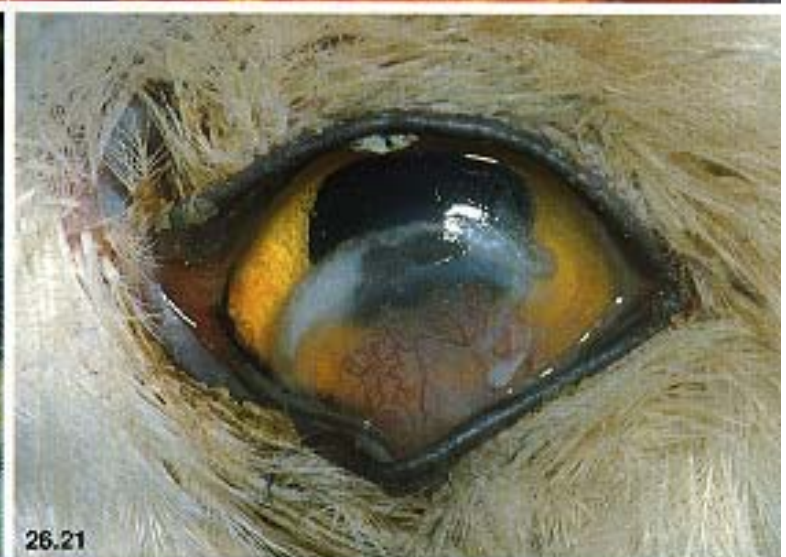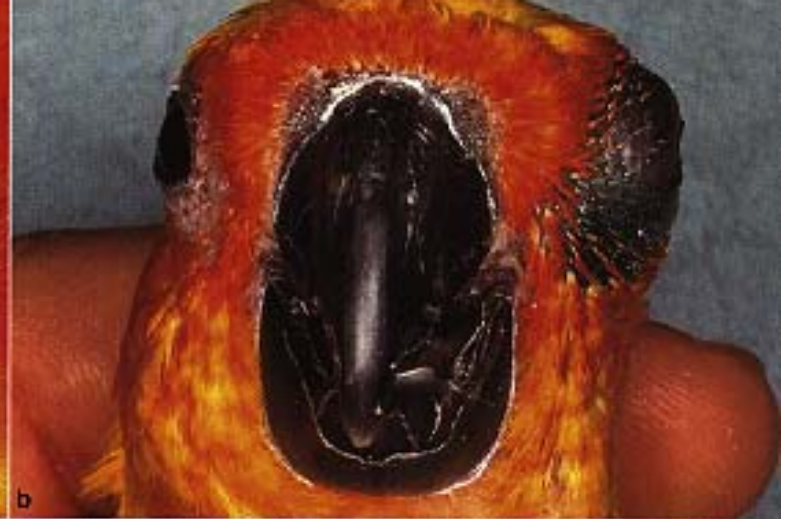Luxation of the lens and uveitis in an owl that was hit by a car. Luxation of the lens may cause an increase in intraocular pressure that must be resolved with an intracapsular lensectomy. Topical steroids were effective in controlling the uveitis in this case (courtesy of S. West).

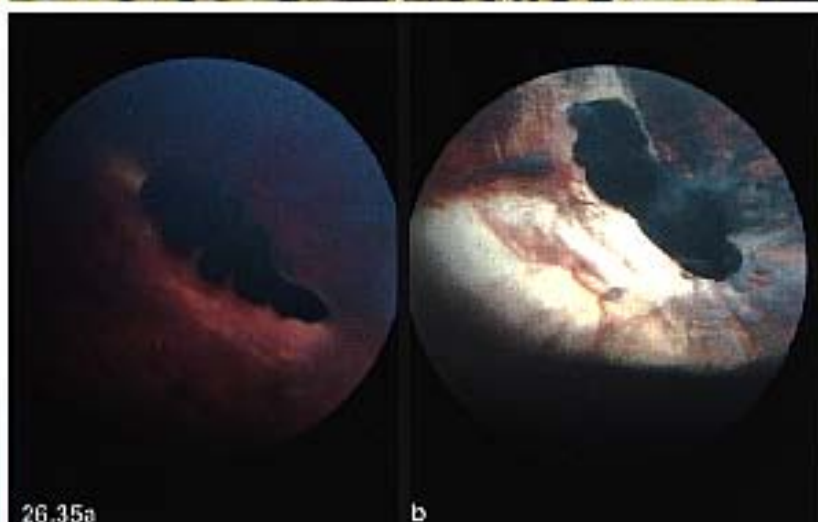
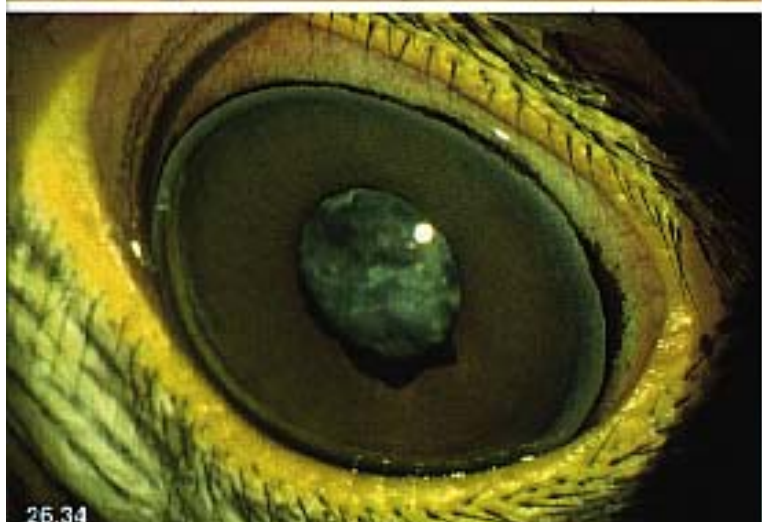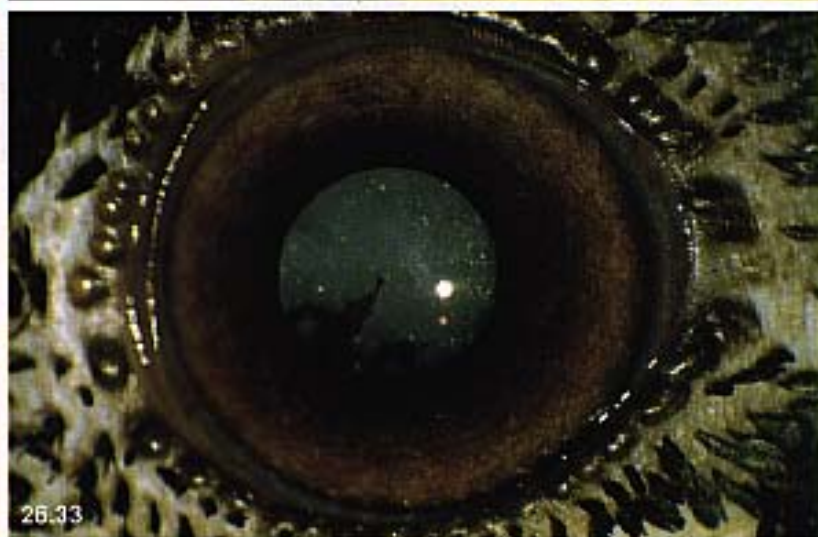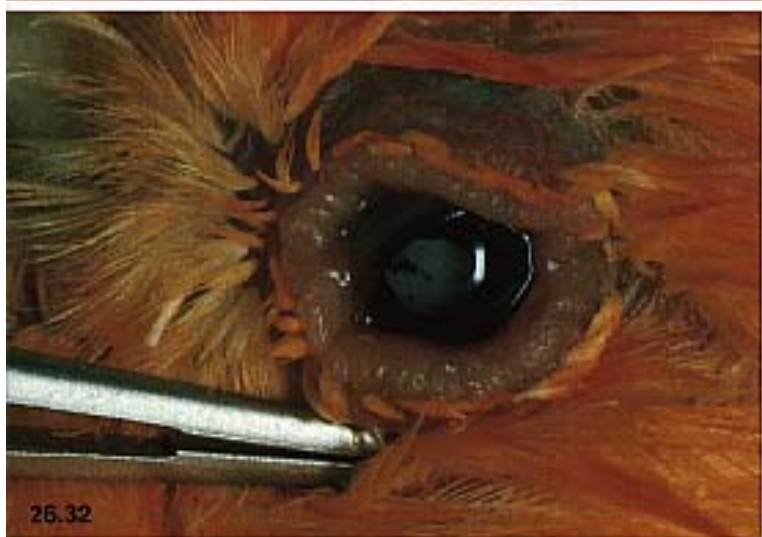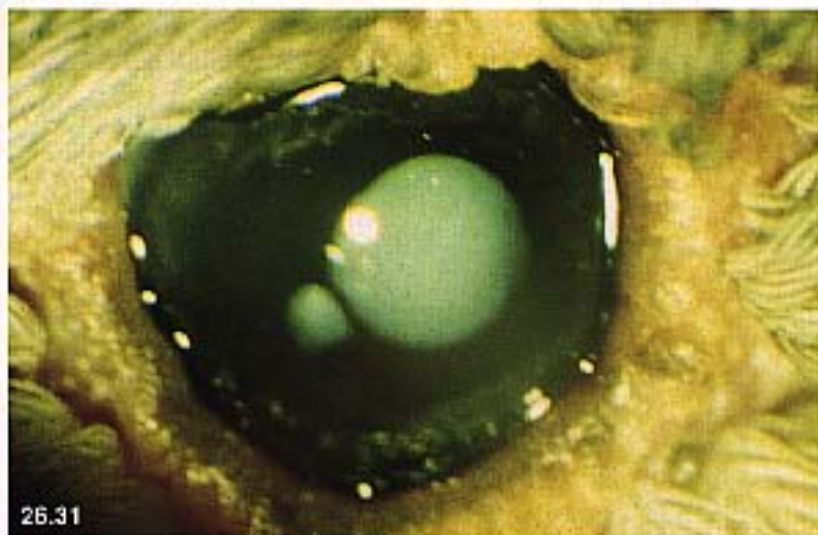
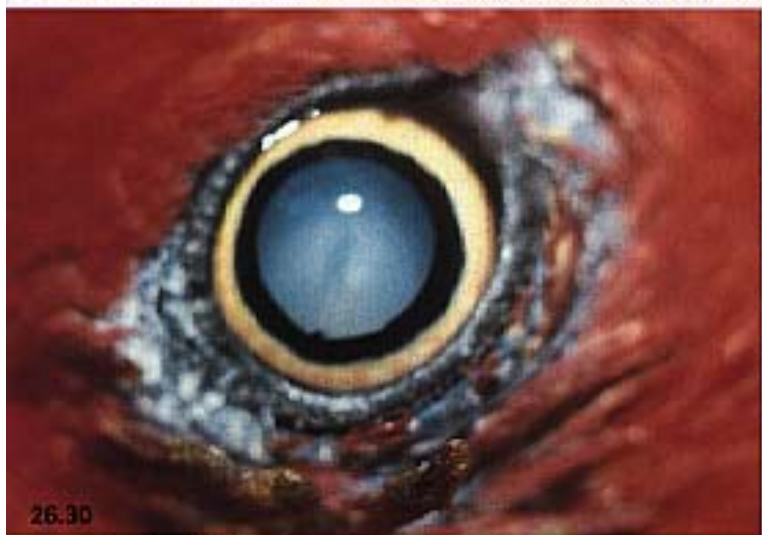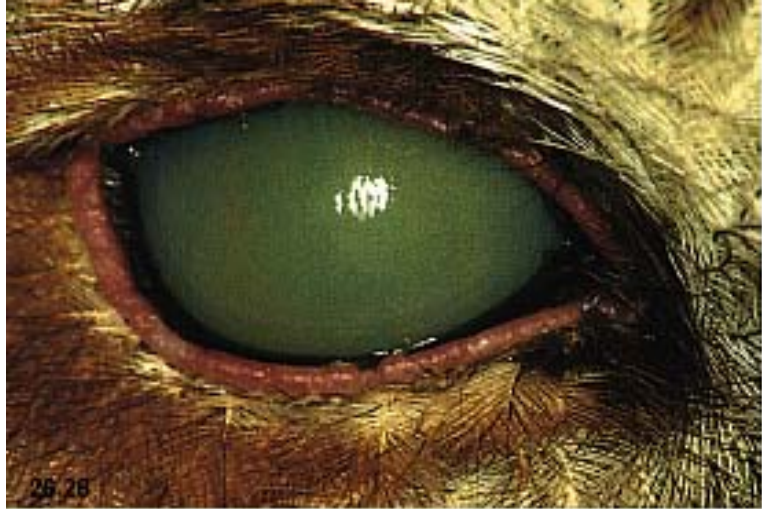Color 26.26

Keratic precipitates on the posterior cornea of a Screech Owl with phacolytic uveitis and bilateral cataracts (courtesy of S. West).

Color 26.27

Uveitis and cataract in an Amazon parrot. Note the darkening and “muddy” appearance of the iris. These changes are characteristic of uveitis not complicated by hypopyon (courtesy of Dan Wolf).





■ Ophthalmology

Color 26.28

Tawny Owl with uveitis. Examination with a slit lamp showed that the white glistening of the eye was caused by hypopyon and not a corneal lesion. Resolution with topical steroid medication was slow and several synechiae remained. No etiologic agent could be identified (courtesy of David Williams).

Color 26.29

An adult male cockatiel was presented with a three-week history of ocular discharge and scratching of the face. A severe panophthalmitis was noted on physical examination. The bird's WBC count was 22,000. A conjunctival scraping revealed numerous gram-negative bacteria, both free and within conjunctival cells. The bird was placed on systemic and ophthalmic antibiotics. Cultures indicated *Pseudomonas* spp. The eye did not respond to therapy, and enucleation was performed six days after initial presentation.

Color 26.30

Cataract in an Eclectus Parrot. The periorbital feather loss is probably secondary to the bird's rubbing the area because of reduced vision in the eye (courtesy of David Williams).

Color 26.31

Inherited cataract in a Norwich Canary. Note also the polycoria probably sub-

sequent to senile iridal atrophy (courtesy of David Williams).

Color 26.32

Cataract and posterior synechiae in a thirteen-year-old canary. Phthisis bulbi with wrinkling of the lid margins are also evident (courtesy of R. Korbel).

Color 26.33

Cataract in a mynah bird with posterior synechiae. In this case, the contralateral eye was unaffected, the bird's behavior was normal and surgical removal of the cataract was not attempted (courtesy of K.C. Barnett).

Color 26.34

Cataract in a Harris Hawk. Note the scintillating appearance of the cataract, indicating some resorption. The iris ectropion is believed to be a congenital anomaly and not reflective of a uveitis. Extracapsular cataract extraction was performed and the bird regained vision in the eye (courtesy of David Williams).

Color 26.35

a) Normal pecten in an Eagle Owl (courtesy of David Williams). **b)** Gross retinal post-inflammatory scarring in a Tawny Owl. It has been suggested, but not confirmed, that this scarring may be a result of toxoplasmosis (courtesy of K.C. Barnett).

32. **Jacobson ER, Gardiner C, Clubb S:** Adenovirus-like infection in white-masked lovebirds (*Agapornis personata*). *J Assoc Avian Vet* 1:32-34, 1989.
33. **Jacobson ER, et al:** Papilloma-like virus infection in an African grey parrot. *J Am Vet Med Assoc* 183:1307-1308, 1983.
34. **Johnson BJ, Castro AE:** Canary pox causing high mortality in an aviary. *J Am Vet Med Assoc* 189:1345, 1986.
35. **Karpinski LG, Clubb SL:** Post pox ocular problems in blue-fronted and blue-headed pionus parrots. *Proc Assoc Avian Vet*, 1985, p 91.
36. **Karpinski LG, Clubb SL:** Clinical aspects of ophthalmology in caged birds. In Kirk RW (ed): *Current Veterinary Therapy IX*. Philadelphia, WB Saunders Co, 1986, pp 616-621.
37. **Kern TJ, Murphy CJ, Heck WR:** Partial upper eyelid agenesis in a peregrine falcon. *J Am Vet Med Assoc* 187:1207, 1985.
38. **Kern TJ, Murphy CJ, Riis RC:** Lens extraction by phacoemulsification in two raptors. *J Am Vet Med Assoc* 185:1403-1406, 1984.
39. **Keymer IF:** Cataracts in birds. *Avian Pathol* 6:335-341, 1977.
40. **Korbel R:** Tonometrie am Vogelauge. III. DVG-Tagung Vogelkrht, München, 1992.
41. **Korbel R, Schäffer EH:** Zum Vorkommen einer konjunktivitis unbekannter Ätiologie bei Wellensittichen (*Melopsittacus undulatus* Shaw, 1805). [Conjunctivitis of unknown pathogenesis in budgerigars.] *Tierärztl Prax* 19: 659-663, 1991.
42. **Koschmann JR:** Vitamin A deficiency in caged birds. *Texas Vet Med J* 48:25, 1986.
43. **Kraft V, Teufel P:** Nachweis eines Pockenvirus bei Zwergpapageien (*Agapornis personata* und *Agapornis roseicollis*). *Berl Munch Tierarztl Wschr* 84:83-87, 1971.
44. **Krehbiel JD:** Cataracts in bobwhite quail. *J Am Vet Med Assoc* 161:634-637, 1972.
45. **Maddux RL, Cgengappa MM, McLaughlin BG:** Isolation of *Actinobacillus suis* from a Canada goose (*Branta canadensis*). *J Wild Dis* 23:483, 1987.
46. **Martin GR:** Eye. In King AS, McLeland J (eds): *Form and Function in Birds Vol 3*. London and New York, Academic Press, 1985.
47. **Martin GR, Gordon IE, Cadle DR:** Electroretinographically determined spectral sensitivity in the tawny owl (*Strix aluco*). *J Comp Physiol* 89:72-78, 1975.
48. **Mason RW:** Conjunctival cryptosporidium in a duck. *Avian Dis* 30:598, 1986.
49. **McCrary MD, Bloom PH:** Lethal effects of introduced grasses on red-shouldered hawks. *J Wildl Mgt* 48:1005-1008, 1984.
50. **McDonald SE, Lowenstein LJ, Aardans AA:** Avian pox in blue-fronted Amazon parrots. *J Am Vet Med Assoc* 179:1218-1222, 1981.
51. **McGaughey CA, Burnet FM:** Avian pox in wild sparrows. *J Comp Path* 55:201-205, 1945.
52. **Meyer DB:** The avian eye and its adaptations. In Crescietti F (ed): *Handbook of Sensory Physiology VII/5*. Berlin and New York, Springer Verlag, 1977.
53. **Mikaelian I, Paillet I, Williams DL:** Comparative use of various mydriatic drugs in the kestrel (*Falco tinnunculus*). *Proc World Vet Conf*, 1991.
54. **Miller WM, Boosinger TR, Maslin WR:** Granulomatous uveitis in an owl. *J Am Vet Med Assoc* 193:365-366, 1988.
55. **Moore CP, Pickett JP, Beehler B:** Extracapsular extraction of senile cataract in an Andean condor. *J Am Vet Med Assoc* 187:1211-1213, 1985.
56. **Murphy CJ:** Raptor ophthalmology. *Comp Cont Ed* 9:241-260, 1987.
57. **Murphy CJ, Kern TJ, Riis RC:** Intraocular trauma in a red-tailed hawk. *J Am Vet Med Assoc* 181:1390-1391, 1982.
58. **Murphy CJ, et al:** Ocular lesions in free-living raptors. *J Am Vet Med Assoc* 181:1302-1304, 1982.
59. **Murphy CJ, et al:** Enucleation in birds of prey. *J Am Vet Med Assoc* 183:1234-1237, 1983.
60. **Murphy CJ, et al:** Retinal dysplasia in a hybrid falcon. *J Am Vet Med Assoc* 187:1208-1209, 1985.
61. **Paul-Murphy J, et al:** Malignant lymphoreticular neoplasm in an African grey parrot. *J Am Vet Med Assoc* 187:1216-1217, 1985.
62. **Pettigrew JD, Wallman J, Wildsoet CF:** Saccadic oscillations facilitate ocular perfusion from the avian pecten. *Nature* 343:362-363, 1990.
63. **Pitts C:** Hypovitaminosis A in psittacines. In Kirk RW (ed): *Current Veterinary Therapy VIII*. Philadelphia, WB Saunders Co, 1985, pp 622-625.
64. **Poonacha KB, Wilson M:** Avian pox in pen-raised bobwhite quail. *J Am Vet Med Assoc* 179:1264, 1976.
65. **Rambow VJ, Murphy JC, Fox JG:** Malignant lymphoma in a pigeon. *J Am Vet Med Assoc* 179:1266-1268, 1981.
66. **Randall CJ:** Conjunctivitis in pheasants associated with cryptosporidial infection. *Vet Rec* 118: 211, 1986.
67. **Randall CJ, et al:** Retinal detachments in the pheasant (*Phasianus colchicus*). *Avian Pathol* 15:687-695, 1986.
68. **Rochon Duvigneaud AJF:** *Les yeux et la vision des vertébrés*. Paris, 1943.
69. **Schlumberger HG:** Neoplasia in the parakeet I. Spontaneous chromophobe pituitary tumors. *Cancer Res* 14:237-245, 1954.
70. **Schmidt RE, Becker LL, McElroy JM:** Malignant intraocular medulloepithelioma in two cockatiels. *J Am Vet Med Assoc* 189:1105-1106, 1986.
71. **Shimakura S, Sawa H, Yamashita T, Hirai K:** An outbreak of ocular disease caused by staphylococcal infection in Amazon parrots (*Amazona aestiva*) imported into Japan. *Jpn J Vet Sci* 43:273, 1981.
72. **Slatter DH, et al:** Hereditary cataracts in canaries. *J Am Vet Med Assoc* 183:872-874, 1983.
73. **Surman PG, Schultz DJ, Tham VL:** Keratoconjunctivitis and chlamydia in cage birds. *Aust Vet J* 50:356, 1974.
74. **Thomas-Baker B, Dew RD, Patton S:** Ivermectin treatment of ocular nematodiasis in birds. *J Am Vet Med Assoc* 189:1113, 1986.
75. **Tudor DC, Yard C:** Retinal atrophy in a parakeet. *Vet Med Sm Anim Clin* 73:85, 1978.
76. **Vickers MC, et al:** Blindness associated with toxoplasmosis in canaries. *J Am Vet Med Ass* 200:1723-1725.
77. **Walls GL:** The vertebrate eye and its adaptive radiation. Cranbrook Inst Sci, Michigan, 1942.
78. **Williams DL:** A wing guided by an eye: A review of raptor ophthalmology. *Vet International* 1:10-17, 1993.
79. **Woerpel RW, Roskopf WJ:** Retro-orbital *Mycobacterium tuberculosis* infection in a yellow-naped Amazon parrot (*Amazona ochrocephala aurogallata*). *Avian/Exotic Prac* 1:7-10, 1984.
80. **Wolf ED, Amass K, Olsen J:** Survey of conjunctival flora in the eye of clinically normal captive exotic birds. *J Am Vet Med Assoc* 183:1232-1233, 1983.
81. **Wood CA:** The fundus oculi of birds especially as viewed by the ophthalmoscope. Lakeside Press, Chicago, 1917.
82. **Zenoble RD, Griffith RW, Clubb SL:** Survey of bacteriological flora of conjunctiva and cornea in healthy psittacine birds. *Am J Vet Res* 44:1966-1967, 1983.