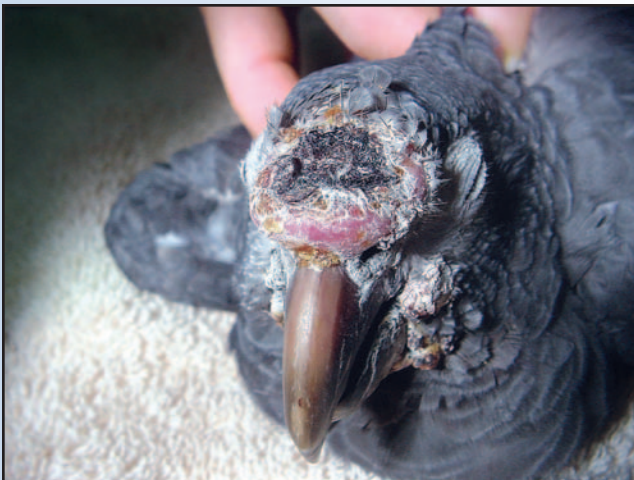

Overview of Tumors

Section I: Clinical Avian Neoplasia and Oncology

Section II: A Retrospective Study of Case
Submissions to a Specialty Diagnostic Service



Overview of Tumors: Section I

Clinical Avian Neoplasia and Oncology

TERESA L. LIGHTFOOT, DVM, Dipl ABVP-Avian

Avian neoplasias encountered in practice include cancer of the skin, oral cavity, sinuses, liver, kidney, reproductive organs, bones, brain, vascular structures and connective tissue. External tumors may be detected by physical examination and can often be diagnosed by needle aspiration, wedge, punch or surgical biopsy. Internal neoplasias often require radiographs, ultrasound, endoscopy, and biopsy or exploratory surgery to identify, diagnose and determine the extent of the neoplastic processes.

Treatment of neoplastic processes in birds is poorly documented. Most reports of treatment protocols are either anecdotal or involve a single patient. Many reports are not published, but are to be found in avian veterinary discussion groups on the Internet.^{35,36,37}

The presentation in this text of these anecdotal treatments is problematic. Failure to include preliminary information regarding efficacy and/or clinical response may reduce the practitioner's willingness and ability to recommend treatment. However, future studies may either reinforce these experimental protocols or they may demonstrate a lack of efficacy or serious side effects of these regimes. The ultimate decision will lie with the knowledgeable practitioner and the well-informed client.

To date, the treatment of avian neoplasia has mirrored treatment in other domestic species. Generally, solid tumors are best treated with surgical excision, while systemic neoplastic processes (ie, systemic lymphoma, metastatic conditions) are most effectively managed with use of systemic chemotherapy. Cases in which surgical excision is incomplete or impossible may benefit from alternative forms of local therapy, including external beam radiation (Cobalt 60 or linear accelerator), cryotherapy, photodynamic therapy or hand-held radiation applicators.

CUTANEOUS MASSES

These may be pseudo-neoplastic conditions such as xanthomas and lipomas, or neoplastic lesions.

Xanthomas

These are generally friable, yellow-colored, fatty-appearing masses that may be located anywhere on the body, but are often seen on the distal wing, in the sterno-pubic area and on the keel (see Chapter 13, Integument). The origin of xanthomas is unknown, however, dietary improvement, including sufficient vitamin A or vitamin A precursors, has been noted to be curative in less advanced cases. Xanthomas tend to be very vascular and surgical excision, when necessary, should be undertaken with due attention to hemostasis. Diffuse xanthomas may be amenable to cryotherapy, but attention must be paid to maintenance of the vascular supply.³⁵

Lipomas

These occur most frequently in budgerigars and are usually located on the keel or in the sterno pubic area. Most early lipomas respond to modified diet therapy. Lipomas that cause clinical signs can be addressed via surgical excision. Malignant liposarcomas are rare in psittacines.³⁵

Mucoepidermoid Carcinomas

Mucoepidermoid carcinomas are rarely reported in birds. In humans, these tumors demonstrate variable degrees of malignancy and surgical resection is often curative. Comparable grading of this type of neoplasia has not been established in the avian patient (Figs 20.1.1, 20.1.2).

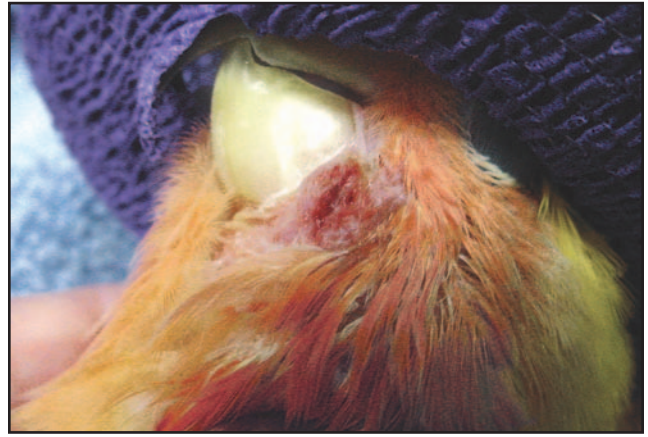Fibrosarcomas

These can occur anywhere on the body, but are most commonly seen in the oral cavity, associated with long bones, or in the abdominal cavity (Figs 20.1.3, 20.1.4).



Lucy Bartlett

Fig 20.1.1 | Mucoepidermoid carcinoma.



Lucy Bartlett

Fig 20.1.2 | Mucoepidermoid carcinoma after resection.

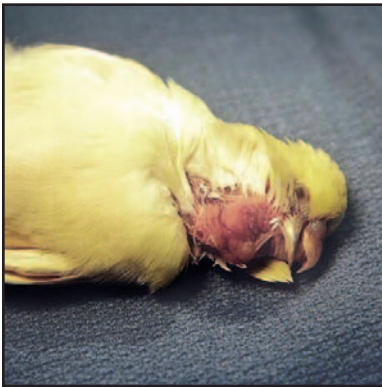

Fig 20.1.3 | Fibrosarcoma on the face of a budgerigar.

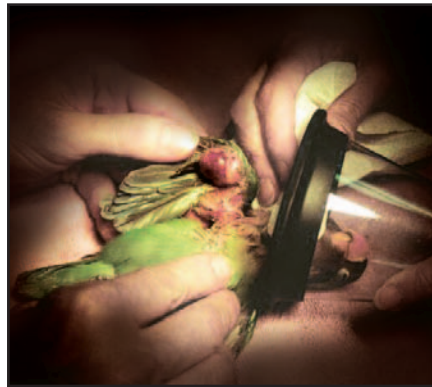

Fig 20.1.4 | Fibrosarcoma on the wing of a lovebird.

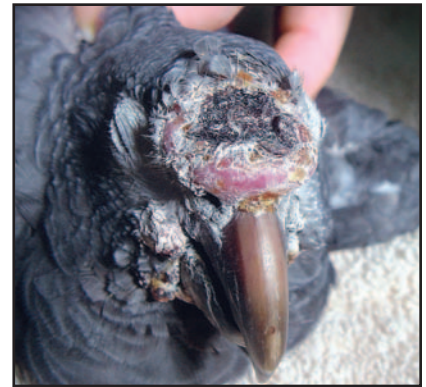

Fig 20.1.5 | Squamous cell carcinoma of the ramphotheca, and papillomatosis in an older Timneh grey parrot.

Fibrosarcomas may be subcutaneous or more deeply located in underlying tissue, and often appear fixed and proliferative with a nodular, red surface. They tend to be locally invasive and often recur with conservative surgical excision. Therefore, additional local treatment in the form of radiation therapy is often indicated for providing long-term local control. As the metastatic rate in other domestic species ranges from 5 to 15%, local disease management is paramount, with metastatic control as a secondary concern. Surgical excision followed by both radiation and chemotherapy has been reported with some success in a few publications.¹⁴ Strontium radiation therapy, although limited by depth of penetration, has been anecdotally reported as efficacious in several instances.³⁵

Squamous Cell Carcinomas

These also may occur anywhere on the body, being most prevalent at mucocutaneous junctions of the head (**Fig 20.1.5**), on the distal wing and on the phalanges. The uropygial (preen) gland also may develop either adenocarcinoma or squamous cell carcinoma. (Note that *Amazona* spp. do not possess a preen gland). Squamous cell carcinomas tend to be extremely locally invasive and

complete excision is rarely accomplished. Radiation therapy has been attempted with some success, however, squamous cell carcinoma appears to be an exceptionally radioresistant tumor and long-term control is rare. Anecdotal reports indicate that radioresistance may be even greater in birds than in mammals.^{19,35} Strontium therapy when tumor depth is not a limiting factor has shown some promise in selected psittacine cases.³⁵ Distant metastasis is rare, therefore chemotherapy is not commonly utilized. Photodynamic therapy (PDT) has been attempted in two reported cases. One case of a squamous cell carcinoma in the beak of a hornbill showed a positive result in decreasing tumor size, but failure to eliminate the neoplasia.³¹ The second case demonstrated a positive response to PDT after each treatment, but treatments were not able to be administered at regular intervals.²⁸

NEOPLASIA OCCURRING IN THE MUSCULOSKELETAL SYSTEM

Theoretically these include the benign lesions such as chondroma and hemangioma, and malignant tumors including osteosarcoma, chondrosarcoma and leiomyosarcoma. Wide surgical resection or amputation are

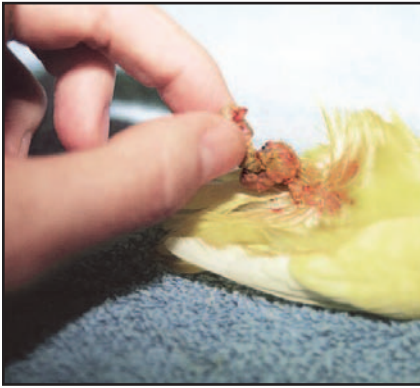

Fig 20.1.6 | Chondroma on the leg of a budgerigar.

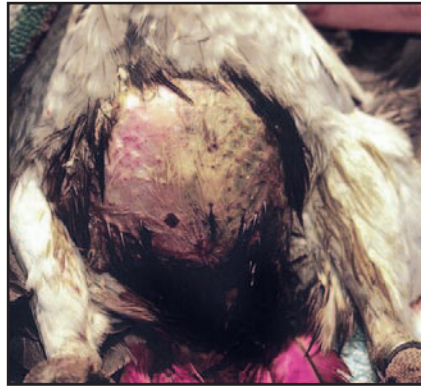


Fig 20.1.7 | Gross appearance of the abdomen in a 9-month-old African grey parrot with diffuse coelomic hemangioma.

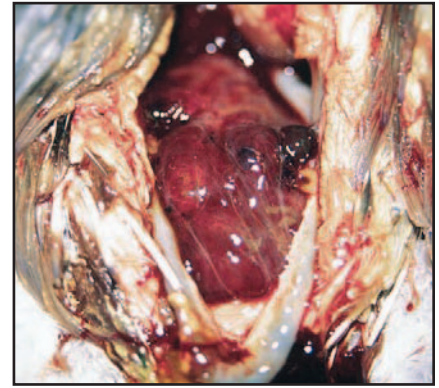


Fig 20.1.8 | The bird in Fig 20.1.11, showing hemangioma encompassing most abdominal viscera.

generally the suggested methods of treatment, as benign lesions are often cured with complete excision and a decrease in tumor burden can be accomplished in malignant lesions. As tumors such as osteosarcoma carry high metastatic rates, additional therapies may be indicated. Extrapolation from canine and feline oncology may suggest other modalities such as radiation therapy for additional local treatment and chemotherapy for systemic control.

Chondromas

Therapy for chondromas generally involves aggressive surgical excision of the affected area (Fig 20.1.6). Radiation and chemotherapy may be considered.

Osteosarcoma

Confirmation of osteosarcoma has rarely been reported in psittacines. Species and anatomic location predilections have not been noted in psittacines. Documentation of classifiable radiographic changes consistent with osteosarcoma is not available for birds.

A biopsy should be obtained from patients where radiographic bony lesions are present. Under inhalant anesthesia, a 22- to 20-gauge needle can be surgically introduced into the bone. A sufficient sample is usually obtained and subsequently retained in the hub of the needle. The sample can then be dislodged with smaller gauge wire and submitted. If a diagnosis of osteosarcoma is received, amputation with follow-up chemotherapy is the current recommended protocol extrapolated from canine medicine.

INTERNAL NEOPLASIA

Hemangiomas

These seem to occur more commonly than hemangiosarcomas in birds. Hemangioma may be internal or external and commonly appears as a red-purple, flat, firm lesion

(see Chapter 13, Integument). Although histopathologically benign, in at least one case in this author's experience, hemangioma occurred in a juvenile African grey (*Psittacus erithacus*) and involved the coelomic cavity, small intestine, liver, lung, air sacs and pericardium. Complete surgical excision could not be accomplished and euthanasia was eventually required (Figs 20.1.7, 20.1.8). Treatment of a hemangiosarcoma with radiation therapy has been reported in one case.⁹

Internal Carcinomas

These are commonly reported in birds and include ovarian neoplasias (of various cell origins), renal carcinomas, hepatic adenocarcinoma, hepatobiliary and pancreatic adenocarcinoma (related to papillomas in Amazons), splenic and gastric carcinomas. Papillary carcinomas of air sac origin are locally invasive and may present as external masses. Anecdotal reports exist indicating intralesional carboplatin therapy may be useful in ovarian and renal adenocarcinoma, generally following surgical debulking and confirmation of the neoplasia on histopathology.^{18,34} Bile duct carcinoma also has been treated with carboplatin successfully in one report.³⁸ Toxicity studies with cisplatin in cockatoos indicate that psittacine tolerance for this drug may be greater than that of mammals.⁸

Tamoxifen administration has not been evaluated for efficacy in cases of avian ovarian carcinoma, but anti-estrogenic activity was suggested and side effects were minimal in one drug trial.¹⁷ GnRH agonists^a have been effective empirically (dosed at 200-800 $\mu\text{g}/\text{kg}$), however, confirmation of neoplasia (as opposed to cystic ovarian disease) has not often been confirmed prior to therapy.^{16,20}

Doxorubicin (adriamycin) is commonly employed in the treatment of carcinomas in human and canine patients. The limiting toxic effects of doxorubicin include myelosuppression and cardiac toxicity. To date, the degree to

which these concerns will apply to avian cancer patients has not been determined. Anecdotal reports of both toxicity and efficacy of doxorubicin in avian patients are currently inconclusive.³⁴ Dosages of 50-60 mg/m² have been used with no adverse reactions. In several cases there has been significant tumor regression (Goldsmith, Lightfoot, unpublished data, 2004).

Carcinomas, generally diagnosed at necropsy, are often found at the proventricular-ventricular junction. Death from this neoplasia may be due to hemorrhage, perforation and sepsis or endotoxic shock, or inanition and subsequent wasting. Metastasis to the lungs has been confirmed in one case report.⁴

Biliary and pancreatic carcinomas are frequently diagnosed in the genus *Amazona* and to a lesser degree, *Ara*, in conjunction with internal papillomatosis.^{11,13} A recent connection to a herpesvirus has been identified (see Chapter 32, Implications of Viruses in Clinical Disorders). Carboplatin has been used in several cases with equivocal results, but with no apparent toxicity.^{7,35,38}

Surgical excision is the treatment of choice with solitary lesions of hepatic cell carcinoma in other species, and is the only documented curative treatment in human medicine. Combinations of chemotherapy and radiation therapy have been used with equivocal results in people in an attempt to prevent or limit metastatic disease. In widely disseminated hepatic carcinoma, palliative chemotherapy is often employed. However, extrapolation from people would indicate that this type of cancer is highly resistant to chemotherapy. The most commonly employed chemotherapeutic agents in human medicine appear to be doxorubicin and 5-fluorouracil (5-FU), however, mean survival times do not appear to be statistically improved in patients with widely disseminated disease. The use of immunotherapy — including interferon, in conjunction with cisplatin, doxorubicin and 5-FU — has shown the most promise to date in human patients. Unfortunately, interferon is limited in its usefulness by cost and availability in veterinary medicine. The efficiency of radiation therapy for carcinomas and other neoplasias is largely unknown. However, tolerance of radiation therapy has been anecdotally reported as greater than anticipated.

Endocrine Neoplasia

Neoplasia of endocrine origin is not frequently reported in birds.

Pituitary Adenomas

These have been documented in multiple avian species, but are most prevalent in budgerigars and cockatiels. Affected animals may present with acute neurologic conditions (seizures/opisthotonos). They also may present



Fig 20.1.9 | Thymoma in a lovebird, intraoperatively.

with conditions related to the pituitary hormone(s) that are affected. Usually, this will be pronounced polydypsia and polyuria. Occasional presentations will be that of a retrobulbar mass and subsequent exophthalmia.²⁷ In human medicine, surgical resection and radiation therapy (if needed) are utilized for treatment. Size and monetary constraints make routine treatment by these methods unlikely in our small psittacine patients.

Thyroid

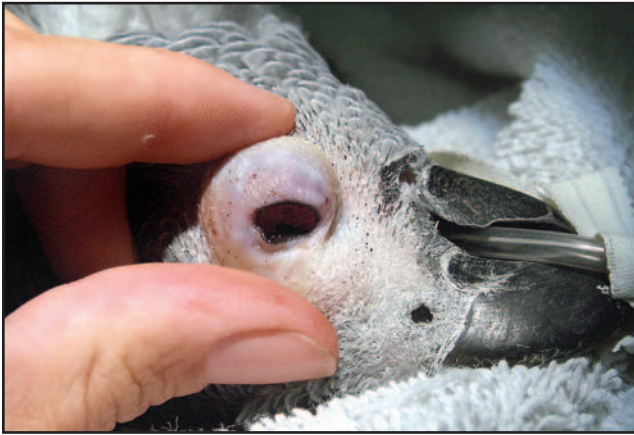Budgerigars that are iodine deficient may develop non-neoplastic thyroid hyperplasia that presents as a thyroid mass, often causing a change in the voice or a respiratory squeak.

Thyroid Tumors

These are not as common in birds as they are in domestic rabbits, but do occur (Fig 20.1.9). They may be intrathoracic or located in the area of the neck. In humans, classification according to cell type (medullary, cortical and mixed) is a prognostic indicator, with cortical tumors having the highest incidence of recurrence and malignancy. Thymoma and thyroid adenocarcinoma have been reported in several psittacine species. Surgical excision is the primary treatment recommendation. Adjuvant radiation and chemotherapy protocols are being utilized in human medicine. Cisplatin is used in many human chemotherapy protocols for thymomas and thymic carcinomas. Limited studies have shown that psittacines may be tolerant of the common side effects induced by cisplatin, and this agent may be useful in the treatment of these neoplasias.

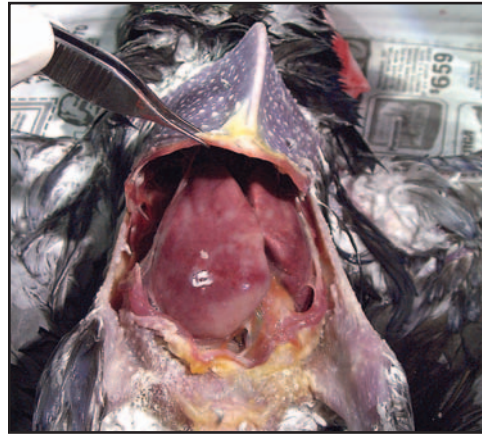Pancreatic Neoplasias

Infrequent accounts of primary pancreatic neoplasia of variable cell origin, not associated with internal papillomatosis, have been reported.²³



Lori Harrison

Fig 20.1.10 | Retrobulbar lymphoma in a young African grey.



Lori Harrison

Fig 20.1.11 | Gross necropsy photo of the liver from the African grey in Fig 20.1.10. A fine-needle aspirate of the liver demonstrated that the lymphoma had spread to involve the hepatic parenchyma.

Respiratory Neoplasia

Primary respiratory neoplasia is uncommon in psittacines.¹² An exception seems to be an intrathoracic neoplasia reported in cockatiels. It is characterized by the inclusion of two cell types, having both mesenchymal and epithelial cell components (see Section II of this chapter). Few other primary pulmonary neoplasias have been reported in the literature.² Metastatic pulmonary neoplasia may occur, but it is not noted with the same frequency as is documented in dogs.⁴

Lymphoma/Lymphosarcoma

Numerous reports of exophthalmos in psittacines, particularly young African greys, have been diagnosed as retrobulbar lymphoma (**Fig 20.1.10**). Differential diagnoses for this condition are pituitary adenoma and hyperplasia or adenoma of the Harderian gland. Lymphoma may have many presentations in pet birds, much as it does in other companion animals (**Fig 20.1.11**). Chemotherapy is the treatment of choice for systemic disease, and surgery and radiation therapies have been successfully employed in cases of solitary lymphoma.^{6,35} To date, no evidence of retroviral activity has been associated with psittacine lymphoma.

The clinician may find it useful to have access to current protocols for lymphoma that are utilized in canine medicine. Tracy LaDue, Diplomate ACVIM-Oncology and ACVR-Radiation Oncology, of Florida Veterinary Specialists in Tampa, Florida, US, has generously provided the following abbreviated outline of therapeutic options and chemotherapeutic agents. These protocols are NOT established for avian patients, but are provided to give the practitioner a point of reference when attempting to design potential therapeutic regimes for birds with lymphoma. Again, species differences in response may well

exist. Some of the chemotherapeutic agents listed may be determined to be either ineffectual or contraindicated in birds. As documentation of these variables occurs, it is hoped that protocols can be developed that will produce more predictable results in the avian patient.

Chemotherapy Protocols for Canine Lymphoma*

(Current recommended canine dosages can be found in Plumb's Veterinary Handbook).

1. Oral Therapies
 - a. Prednisolone and cyclophosphamide
 - b. Lomustine (CCNU)
2. Injectable Therapy
 - a. COP-L Protocol
 - i. L-asparaginase injection
 - ii. Oral prednisolone (tapering dose)
 - iii. Oral weekly cyclophosphamide
 - iv. Vincristine injections weekly IV
 - b. Single-agent adriamycin injections q 3 weeks IV
 - c. UW-Madison Cyclic Combination
 - i. L-asparaginase
 - ii. Vincristine
 - iii. Cyclophosphamide
 - iv. Adriamycin
 - v. Prednisolone

Applicable testing (CBC, biochemistries, cardiac evaluation) should be performed to assess the initial and intra-therapeutic health of the patient.

*It must be emphasized again that these protocols are designed for *canine* patients. Extrapolation to avian patients must be undertaken with the knowledge that efficacy and potential side effects have not been documented.

CHEMOTHERAPEUTIC AGENTS

Anticancer agents are typically broken into six categories based on their mechanism of action.

1. Alkylating agents such as cyclophosphamide and lomustine prevent cell replication by covalently binding to the nucleotide bases of the DNA molecule.
2. Antimetabolites will mimic purine, pyrimidine or metabolite precursors of the nucleotide bases, resulting in non-functional DNA.
3. Steroids such as prednisone and prednisolone cause lympholysis and suppress neutrophil function and antibody production.
4. Plant alkaloids such as vincristine bind to microtubules to prevent normal formation and function of the mitotic spindle. The antibiotics such as adriamycin intercalate between DNA base pairs to disrupt transcription and also cause oxygen free radical damage.
5. Miscellaneous drugs such as the Platinol compounds (cisplatin and carboplatin) also bind to bases of the DNA preventing replication, but have a bifunctional ability with double attachment to DNA strands.
6. L-asparaginase hydrolyzes asparagine to aspartic acid and ammonia, resulting in loss of an essential amino acid for cell function.

Most anticancer agents have associated vomiting, diarrhea and bone marrow suppression as sequelae. It is important to monitor patients for signs of dehydration or secondary infection as a result of chemotherapy administration. Some anticancer agents have particular toxicities known to that drug alone, such as sterile hemorrhagic cystitis due to cyclophosphamide metabolites in dogs and people. Such toxicities are not well reported in avian species and should be monitored for accordingly.

When confronted with a confirmed diagnosis of neoplasia, a current literature search is warranted due to the rapid advances and changes in treatment recommendations. Consultation with a veterinary oncologist will increase the likelihood of selecting an appropriate treatment regime and properly administering the chosen therapy.

Products Mentioned in Text

a. Depo-Lupron, Pharmaceuticals, Inc, Deerfield, IL USA, 800-622-2011

References and Recommended Reading

1. Altman RA, et al (eds): Avian Medicine and Surgery. Philadelphia, WB Saunders Co, 1997.
2. Andre JP, Delverdier M: Primary bronchial carcinoma with osseous metastasis in an African grey parrot (*Psittacus erithacus*). J Avian Med Surg 13(3):180-186, 1999.
3. Burgmann PM: Common psittacine dermatologic diseases. Sem Avian Exotic Pet Med 4(4):169-183, 1995.
4. Campbell TW: Carcinoma of the ventriculus with metastasis to the lungs in a sulphur-crested cockatoo (*Cacatua galerita*). J Avian Med Surg 13(4):265-268, 1999.
5. Clyde VL, Orosz SE, Munson L: Severe hepatic fibrosis and bile duct hyperplasia in four Amazon parrots. J Avian Med Surg 10(4):252-257, 1996.
6. Coleman CW: Lymphoid neoplasia in pet birds: A review. J Avian Med Surg 9(1):3-7, 1995.
7. Degernes LA: Multicystic biliary adenocarcinoma in a blue-and-gold macaw (*Ara ararauna*). J Avian Med Surg 12(2):100-107, 1998.
8. Filippich LJ: Intravenous cisplatin administration in sulphur-crested cockatoos (*Cacatua galerita*): Clinical and pathological observations. J Avian Med Surg 15(1):23-30, 2001.
9. Freeman KP: Radiation therapy for hemangiosarcoma in a budgerigar. J Avian Med Surg 13(1):40-44, 1999.
10. Hahn KA, Jones MP, Petersen MG: Metastatic pheochromocytoma in a parakeet. Avian Dis 41(3):751-4, 1997.
11. Hillyer EV, et al: Bile duct carcinoma in two out of ten Amazon parrots with cloacal papillomas. J Assoc Avian Vet 5(2):91-95, 1991.
12. Jones MP, Orosz SE: Pulmonary carcinoma with metastases in a Moluccan cockatoo (*Cacatua moluccensis*). J Avian Med Surg 15(2):107-113, 2001.
13. Kennedy FA, Sattler-Augustin S: Oropharyngeal and cloacal papillomas in two macaws (*Ara spp.*) with neoplasia with hepatic metastasis. J Avian Med Surg 10(2):89-95, 1996.
14. Lamberski N, Theon AP: Concurrent irradiation and intratumoral chemotherapy with cisplatin for treatment of a fibrosarcoma in a blue and gold macaw (*Ara ararauna*). J Avian Med Surg 16(3):234-238, 2002.
15. Lennox AM: The Use of Aldara (Imiquimod) for the Treatment of Cloacal Papillomatosis in Psittacines. Exotic DVM 4(3):34-35 July 2002.
16. Lightfoot TL: Avian Common Clinical Presentations: Neoplastic, Toxic, Viral and Miscellaneous. Proc Atlantic Coast Vet Conf, 2001.
17. Lupu CA: Evaluation of Side Effects of Tamoxifen in Budgerigars, (*Melopsittacus undulatus*). J Avian Med Surg 14(4):237-242 Dec 2000.
18. MacWhirter P: Use of Carboplatin in the Treatment of Renal Adenocarcinoma in a Budgerigar. Exotic DVM 4(2):11-12 May 2002.
19. Manucy TK, Bennett RA, Greenacre C: Squamous cell carcinoma of the mandibular beak in a Buffon's macaw (*Ara ambiguus*). J Avian Med Surg 12(3):158-166, 1998.
20. Morrissey JK: Gastrointestinal Diseases of Psittacine Birds. Sem Avian Exotic Pet Med 8(2):66-74, 1999.
21. Orosz, SE, Ensley PK, Haynes CJ: Avian Surgical Anatomy. Philadelphia, WB Saunders Co, 1992.
22. Ottinger MA: Neuroendocrine Regulation of Reproduction in Birds and Clinical Applications of GnRH Analogues in Birds and Mammals. Sem Avian Exotic Pet Med 11(2):71-79 April, 2002.
23. Rae M: Endocrine Disease in Pet Birds. Semin Avian Exotic Pet Med 4(1):32-38 Jan 1995.
24. Ramos-Vara JA: Lymphosarcoma with plasmacytoid differentiation in a scarlet macaw (*Ara macao*). Avian Dis 41(2):499-504 Apr-Jun 1997.
25. Ritchie B, Harrison GJ, Harrison LR (eds): Avian Medicine: Principles and Application. Lake Worth, FL, Wingers Publishing, Inc, 1994.
26. Ritchey JW, Degernes LA, Brown TT Jr: Exocrine pancreatic insufficiency in a yellow-naped Amazon (*Amazona ochrocephala*) with pancreatic adenocarcinoma. Vet Pathol 34(1):55-7 1997.
27. Romagnano A, Mashima TY: Pituitary Adenoma in an Amazon Parrot. J Avian Med Surg 9(4):263-270, 1995.
28. Rosenthal K, et al: A Report of Photodynamic Therapy for Squamous Cell Carcinoma in a Cockatiel. Proc Ann Conf AAV 2001, pp 175-176.
29. Schmidt RE: Selected Neoplasia of the Avian Integument. Exotic DVM Vol 4(2):13-14, 2002.
30. Sturkie PD, Whittow GC (eds): Sturkie's Avian Physiology 5th ed. San Diego, Academic Press, Harcourt Brace and Co, 2000.
31. Suedmeyer WK: Attempted Photodynamic Therapy of Squamous Cell Carcinoma in the Casque of a Great Hornbill (*Buceros bicornis*). J Avian Med Surg 15(1):44-49, 2001.
32. Tell LA, Woods L, Mathews KG: Basal cell carcinoma in a blue-fronted amazon parrot (*Amazona aestiva*). Avian Dis 41(3):755-9 Jul-Sep 1997.
33. Tully T: Liposarcomas In A Monk Parakeet (*Myiopsitta monachus*). J Assoc Avian Vet 8(3):120-124 Fall 1994.
34. Watson CL, Lucroy MD: Primary Appendicular Bone Tumors in Dogs. Compend Contin Edu Pract Vet 24(2):128-138 Feb 2002.
35. www.vin.com, Member Search - Species: Bird, Subject: Neoplasia
36. www.exoticdvm.com
37. www.avianmedicine.net
38. Zantop DA: Treatment of bile duct carcinoma in birds with carboplatin. Exotic DVM 2(3):76-78, 2000.

Overview of Tumors: Section II

A Retrospective Study of Case Submissions to a Specialty Diagnostic Service

MICHAEL M. GARNER, DVM, Dipl ACVP

The occurrence of various types of avian neoplasia has been comprehensively reviewed.⁶ This section documents the prevalence of neoplasms in 22 avian orders submitted to a specialty diagnostic service (Northwest ZooPath, Monroe, WA) from 1994 to 2002. Cases were selected based on histologic diagnosis. Cysts, hyperplastic processes, fibromatous polyps and poxvirus-related proliferative lesions were not included. Cases diagnosed as neoplastic based on cytology alone also were excluded. Although potentially reversible and not considered true neoplasms, adenomatous polyps and papillomas were included because of the known association of these lesions with concurrent neoplasia in psittacine birds.⁴ Type, location, biological behavior and patient outcome are addressed. Apparent trends for particular types of neoplasms in some orders or species also are identified and discussed. For the purposes of this manuscript, prevalence refers to a given percentage within the study population, and the study population comprises the cases submitted to the service. The prevalence of these neoplasms in the populations from which these birds originated is not known.

Table 20.2.1 lists the tumor submissions by site and biological behavior. Skin was the most common site for tumor development, followed by alimentary tract, reproductive tract and liver. In all locations except alimentary tract, malignant tumors were more common than benign tumors; the large numbers of cloacal and oral papillomas and adenomatous polyps in psittacine birds account for this variation in behavior.

Table 20.2.2 summarizes total numbers of submissions and total numbers of tumors for each order. For the study period, 9574 avian samples were submitted, representing 22 orders; 557 neoplastic processes were identified, for an overall prevalence of 5.8%. The overall

prevalence of neoplasia over the 7-year period was highest in Anseriformes (ducks, geese, swans), Galliformes (poultry, pheasants), Strigiformes (owls) and Cuculiformes (cuckoos, turacos).

Tables 20.2.3 and 20.2.4 list the tumor submissions by type and biological behavior. The most common types of tumors were cutaneous squamous cell carcinoma, multicentric lymphoma, cutaneous soft tissue sarcoma, biliary adenocarcinoma and ovarian/oviduct adenocarcinoma.

Neoplasia by Avian Order

PSITTACIFORMES

Order Psittaciformes (parrots and related species) had 3545 representatives and 220 neoplastic processes (prevalence = 6.2%) (see **Table 20.2.2**), slightly higher than the average prevalence for tumor submissions from other orders. **Table 20.2.5** summarizes the most common presentations of neoplasms within this order. Trend criteria were based on total number of tumor types in a species (two or more), and percent of total for all tumors in a species (10% or greater). Using these criteria, numerous trends were observed within this order. For cockatiels (*Nymphicus hollandicus*), trends were identified in soft tissue sarcoma, squamous cell carcinoma, ovarian/oviduct adenocarcinoma, fibrosarcoma and seminoma. For Amazon parrots (*Amazona* spp.), trends were identified for squamous cell carcinoma, cloacal adenomatous polyp, cloacal papilloma and biliary adenocarcinoma. For macaws (*Ara* spp.), trends were identified for cloacal adenomatous polyp, cloacal papilloma and biliary adenocarcinoma. For cockatoos (*Cacatua* spp.), trends were identified for soft tissue sarcomas and cloacal adenomatous polyps. For budgerigars (*Melopsittacus undulatus*),

Table 20.2.1 | Tumor Submissions by Site and Biological Behavior

Location	Total	Malignant	Benign
Skin	120	92	28
Alimentary	67	32	35
Reproductive	64	59	5
Liver	54	45	9
Kidney	28	17	11
Respiratory	20	20	0
Intracoelomic	17	16	1
Pancreas	13	12	1
Endocrine	13	6	7
Uropygial gland	8	7	1
Musculoskeletal	7	7	0
Thymus	5	4	1
Conjunctiva	5	2	3
CNS	3	3	0
Spleen	2	1	1
Heart	2	2	0

Table 20.2.2 | Total Submissions and Prevalence of Neoplasia by Order

Order	Cases	Tumors	%
Anseriformes	1024	119	11.6
Strigiformes	131	13	9.9
Galliformes	783	74	9.4
Cuculiformes	62	5	8.1
Psittaciformes	3545	220	6.2
Columbiformes	294	17	5.8
Sphenisciformes	204	11	5.4
Phoenicopteriformes	265	13	4.9
Coraciiformes	192	9	4.7
Unknown	44	2	4.5
Gruiformes	249	11	4.4
Falconiformes	272	10	3.7
Ciconiiformes	307	11	3.6
Struthioniformes	111	3	2.7
Charadriiformes	240	6	2.5
Coliiformes	51	1	2.0
Piciformes	198	4	2.0
Passeriformes	1441	27	1.8
Pelecaniformes	58	1	1.7
Apodiformes	19	0	0.0
Procellariiformes	6	0	0.0
Gaviiformes	63	0	0.0
Caprimulgiformes	15	0	0.0
Totals	9574	557	5.8

Table 20.2.3 | Epithelial, Gonadal and Bimorphic Neoplasms^a: Total Numbers, Biological Behavior and Patient Outcome

Tumor Type	Tumor #	Invasive Behavior	Lymphatic invasion	Meta-stasis	Death Due to Tumor	Death Due to Other	Excised	Lost to follow up
Malignant neoplasms								
Squamous cell carcinoma	48	48	1	4	16	0	3	29
Biliary adenocarcinoma	29	29	0	5	28	0	0	1
Ovarian/oviduct adenocarcinoma	28	28	2	9	19	2	0	7
Renal adenocarcinoma	16	16	0	1	15	0	0	1
Seminoma	15	15	0	0	5	8	3	3
Pancreatic adenocarcinoma	13	13	0	7	13	0	0	0
Intracoelomic adenocarcinoma	12	12	0	5	12	0	0	0
Hepatocellular carcinoma	11	11	0	3	10	1	0	0
Proventricular adenocarcinoma	10	10	0	4	10	0	0	0
Air sac adenocarcinoma	9	9	1	4	8	0	0	1
Pulmonary adenocarcinoma	6	6	0	0	6	0	0	0
Ventricular adenocarcinoma	5	5	1	1	5	0	0	0
Cloacal adenocarcinoma	4	4	0	0	1	0	0	3
Sertoli cell tumor	4	4	1	1	1	3	0	0
Bimorphic pulmonary tumor	4	4	0	1	4	0	0	0
Thyroid adenocarcinoma	3	3	0	0	3	0	0	0
Interrenal cell carcinoma	2	2	0	1	2	0	0	0
Nephroblastoma	2	2	0	0	1	1	0	0
Benign neoplasms								
Papilloma	21	0	0	0	0	2 ^b	1	18
Adenomatous polyp	17	0	0	0	0	5 ^c	1	11
Renal adenoma	12	0	0	0	6	6	0	0
Hepatoma	4	0	0	0	2	1	0	1
Thyroid adenoma	4	0	0	0	1	3	0	0
Interrenal cell adenoma ^d	3	0	0	0	0	3	0	0
Biliary adenoma/cystadenoma	3	0	0	0	0	4	0	1
Granulosa cell tumor	2	0	0	0	1	1	0	0
Folliculoma	2	0	0	0	0	0	1	1

a. For all tumors represented two or more times in the study. Tumors represented only once not included.

b. One psittacine cloacal papilloma was associated with concurrent fatal biliary adenocarcinoma, and one psittacine ingluvial papilloma underwent transformation to fatal squamous cell carcinoma.

c. Four psittacine cloacal adenomatous polyps transformed locally to adenocarcinomas. Two psittacines with cloacal adenomatous polyps had concurrent fatal biliary adenocarcinoma, and two psittacines with cloacal adenomatous polyps had concurrent fatal pancreatic adenocarcinoma.

d. The function of interrenal cells (cells of the avian adrenal gland) is analogous to cortical cells of the mammalian adrenal gland.

Table 20.2.4 | Mesenchymal Neoplasms^a: Biological Behavior and Patient Outcome

Tumor Type	Tumor #	Invasive Behavior	Lymphatic Invasion	Metastasis	Death Due to Tumor	Death Due to Other	Excised	Lost to follow up
Malignant tumors								
Lymphoma	40	40	0	36 ^b	36	0	0	4
Soft tissue sarcoma ^c	36	33	1	4	15	2	6	13
Fibrosarcoma	19	19	0	0	6	2	1	10
Hemangiosarcoma	11	11	0	3	9	0	1	1
Osteosarcoma	6	6	0	1	5	0	1	1
Myelolipoma	5	5	0	0 ^d	5	0	0	0
Nerve sheath	4	4	0	0	0	0	1	3
Melanoma	4	4	0	2	3	1	0	0
Thymoma	4	4	0	0	1	0	0	3
Liposarcoma	2	2	0	0	0	0	0	2
Lymphoproliferative disease	2	2	0	1*	2	0	0	0
Benign tumors								
Lipoma	16	0	0	0	0	0	3	13
Hemangioma	8	0	0	0	1	1	2	4
Myelolipoma	2	0	0	0	0	1	1	0

*multicentric

- a. For all tumors represented two or more times in the study. Tumors represented only once not included.
- b. Lymphoma is generally a multicentric process. In 35 birds, the tumor was considered multicentric rather than metastatic, based on the presence of neoplastic cells in at least two different tissue types. In only one dead bird with full tissue evaluation was lymphoma detected in only one tissue (thymus). The remaining four cases were single tissue biopsies that were lost to follow-up, but also were likely multicentric tumors. Two cases had apparent concurrent lymphoid leukemia, based on histologic evaluation.
- c. Tumors were classified as soft tissue sarcomas if they were undifferentiated or had too much anaplasia to determine the cell of origin. Likely differentials were fibrosarcoma, leiomyosarcoma, rhabdomyosarcoma, synovial sarcoma, neurofibrosarcoma, myxosarcoma and amelanotic melanoma.
- d. Intracoelemic myelolipomas were invasive and infiltrated many visceral tissues. It was difficult to determine if some visceral foci were extensions of the invasive process or represented metastatic lesions.

Table 20.2.5 | Prevalence of Most Common Types of Neoplasms in Psittacine Birds

Tumor Type and % of Total Psittacine Cases (220)	Species and Total # of Tumors							
	Cockatiel (39)	Amazon (30)	Macaw (28)	Cockatoo (25)	Budgerigar (25)	Lovebird (19)	African Grey (8)	Rosella (3)
Soft tissue sarcoma - 23 (10.5%)	6 (15%)	0	2 (7%)	4 (16%)	4 (16%)	4 (21%)	1 (12.5%)	0
Squamous cell carcinoma - 22 (10%)	7 (18%)	3 (10%)	1 (4%)	0	5 (20%)	0	2 (25%)	2 (67%)
Cloacal adenomatous polyp - 15 (6.8%)	0	4 (13%)	4 (14%)	4 (16%)	0	0	1 (12.5%)	0
Ovarian/oviduct adenocarcinoma - 13 (5.9%)	7 (18%)	0	1 (4%)	2 (8%)	0	1 (5%)	0	0
Cloacal papilloma - 12 (5.5%)	0	4 (13%)	7 (25%)	0	0	0	1 (12.5%)	0
Fibrosarcoma - 11 (5%)	2 (5%)	0	0	2 (8%)	4 (16%)	2 (11%)	0	0
Biliary adenocarcinoma - 11 (5%)	0	4 (13%)	3 (11%)	0	0	1 (5%)	0	0
Lymphoma - 8 (3.6%)	0	2 (7%)	1 (4%)	0	1 (4%)	3 (16%)	1 (12.5%)	0
Seminoma - 7 (3.2%)	3 (7.6%)	0	1 (4%)	0	1 (4%)	0	0	0
Renal adenocarcinoma - 6 (2.7%)	0	0	1 (4%)	1 (4%)	4 (16%)	0	0	0

trends were identified for soft tissue sarcoma, squamous cell carcinoma, fibrosarcoma and renal adenocarcinoma. Interestingly, although lipomas are recognized as a common tumor in budgerigars,^{6,12} a trend was not identified in this analysis of submissions. This may be because clinicians easily recognize these tumors, thus biopsies are not routinely submitted. For lovebirds (*Agapornis* spp.), trends were identified for soft tissue sarcoma, fibrosarcoma and lymphoma. For African greys (*Psittacus erithacus*) and rosellas (*Platycercus* spp.), trends were identified for squamous cell carcinoma.

Cloacal Adenomatous Polyps and Papillomas

Cloacal adenomatous polyps were common in Amazon parrots and macaws, and also were seen in cockatoos

(*Cacatua* spp.), an African grey, a thick-billed parrot (*Rhynchopsitta pachyrhyncha*) and a Patagonian conure (*Cyanoliseus patagonus*). This distribution is similar to that of retrospective studies of this condition.^{4,14} Malignant transformation of cloacal “papillomas” has been described in psittacine birds.^{6,14} In this study, four cloacal adenomatous polyps (two macaws, one amazon parrot and one cockatoo) underwent local transformation to adenocarcinoma, although no metastases were seen. Adenomatous polyps also were noted in the proventriculus of a cockatoo and on the eyelid of a cockatiel. Two cloacal adenomatous polyps were associated with concurrent biliary adenocarcinoma and two with concurrent pancreatic adenocarcinoma. Cloacal papillomas also were common in macaws and Amazon parrots, and one

was seen in an African grey. Concurrent or isolated oral/choanal papillomas were occasionally seen. Only one of the cloacal papillomas was associated with concurrent biliary adenocarcinoma, and none were associated with malignant transformation in the cloaca.

Proliferative lesions of the cloacal mucosa of psittacine birds are well recognized.^{4,6,14} Although typically referred to as papillomas, there are different morphologic presentations: a papilliform proliferation of squamous mucosal epithelial cells resembling a typical papilloma; and an adenomatous proliferation of glandular and villous mucosa more typical of a polyp, perhaps best termed an adenomatous polyp. Although the morphologic features of cloacal adenomatous polyps and papillomas differ, it is possible that these represent different morphologic variants of the same disease process. Both have similar site and species predilections, and both are sometimes associated with concurrent pancreatic and biliary malignancies. However, the distinction between cloacal adenomatous polyps and papillomas may not be purely academic. Based on this collection of the two cloacal phenotypes, the adenomatous polyps appear to have the most potential for undergoing malignant transformation in the cloaca, and for being associated with concurrent pancreatic or biliary neoplasia. Cloacal papillomas have been associated with herpesvirus gene sequences.^{5,13}

Bimorphic Pulmonary Neoplasms of Cockatiels

Four separate cases of an unusual malignant pulmonary neoplasm were seen in cockatiels. The birds presented with a history of dyspnea and usually had a radiographically apparent mass in the thoracic region of the coelomic cavity. Microscopically, the tumor involved the lung and spread by extension to serosal surfaces of viscera, especially heart and air sacs. One case of possible metastasis to the endocardial surface also was seen. The tumor appeared to arise within the pulmonary parenchyma, around the parabronchi. These neoplasms have unusual cell morphology and are characterized by densely cellular sheets of round to elongate cells with large vesicular to amphophilic smudged nuclei. The cells stain positively for mammalian vimentin, a mesenchymal cell marker, and have cytoplasmic intermediate filaments consistent with vimentin, suggesting that the cells are of mesenchymal origin. The cells stain negatively for mammalian epithelial pan cytokeratins; however, desmosomes, a feature of epithelial cells, are occasionally seen between adjacent cells. The cell of origin is poorly understood, but the tumors appear to be “bimorphic” with mesenchymal and epithelial cell components. The nuclear characteristics of the neoplastic cells resemble the inclusions caused by polyomavirus, but no virus has been detected by electron microscopy, in situ hybridization or PCR (M.M. Garner, unpublished data).

GALLIFORMES

Order Galliformes (chickens, turkeys, pheasants, peafowl) had 783 representatives and 74 tumors (9.5%) (see Table 20.2.2), considerably higher than the average for tumor submissions from other orders. Table 20.2.6 summarizes the most common presentations of neoplasms within this order. Trend criteria were based on total number of a tumor type in a species (two or more), and percent of total for all tumors in a species (10% or greater). Using these criteria, numerous trends were observed within this order. For chickens, trends were identified for lymphoma, ovarian/oviduct adenocarcinoma and squamous cell carcinoma. These tumors are well recognized in poultry.^{2,10,11,16} Some of these tumors, particularly the lymphoid malignancies, may have been associated with or induced by viral infection.^{2,10,11,16} The only identifiable trend in pheasants was for interrenal cell adenoma, an otherwise uncommon tumor in birds. For guinea fowl, trends were identified for squamous cell carcinoma, seminoma and hepatocellular carcinoma. The only trend identified in peafowl was lymphoma. For turkeys, trends were identified for ovarian/oviduct adenocarcinoma and lymphoma. Herpesviruses and retroviruses have been identified as important causes of neoplasia in gallinaceous birds, particularly chickens and turkeys,^{2,10,11,16} and it is possible that viral oncogenesis was a factor in many of the cases within this order; however, serologic and other ancillary testing for viral causes was not routinely performed on case submissions, so viral status of affected birds was generally not known.

ANSERIFORMES

Order Anseriformes (ducks, geese, swans) had 1024 representatives and 119 tumors (11.6%) (see Table 20.2.2), considerably higher than the average for tumor submissions from other orders. All the birds were adults or aged and most tumors likely occurred spontaneously. Trend criteria were based on total number of a tumor type in a species (two or more), and percent of total for all tumors in a species (10% or greater). Using these criteria, only two trends were identified: lymphoma and biliary adenocarcinoma in ducks, although a broad spectrum of neoplastic processes was represented in this group.

PASSERIFORMES

Order Passeriformes (songbirds) had 1441 representatives and only 27 tumors (1.9%) (see Table 20.2.2), considerably below the average for other orders, suggesting that spontaneous neoplasia in passerine birds is relatively uncommon. All birds were adults, a broad spectrum of neoplastic processes was represented and tumors likely occurred spontaneously in most cases. One possible trend was observed: two mynahs had

Table 20.2.6 | Prevalence of Most Common Types of Neoplasms in Galliform Birds

Tumor Type and % of Total Galliform Cases (74)	Total # of Tumors per Species				
	Chicken ^a (37)	Pheasant (5)	Guinea fowl (8)	Peafowl (5)	Turkey (10)
Lymphoma - 12 (16.2%)	6 (16%)	0	0	2 (40%)	4 (40%)
Squamous cell carcinoma - 9 (12.1%)	4 (11%)	0	3 (38%)	1	0
Ovarian/oviduct adenocarcinoma - 8 (10.8%)	6 (16%)	0	0	0	2 (20%)
Renal Adenocarcinoma - 4 (5.4%)	2 (5%)	1 (20%)	0	0	1 (10%)
Pancreatic adenocarcinoma - 4 (5.4%)	3 (8%)	0	0	0	1 (10%)
Seminoma - 4 (5.4%)	0	0	2 (25%)	0	1 (10%)
Interrenal cell adenoma - 3 (4.1%)	0	2 (40%)	0	1 (20%)	0
Hepatocellular carcinoma - 3 (4.1%)	1	0	2 (25%)	0	0

a. Includes chickens, roosters, jungle fowl

hepatic malignancies and concurrent hemochromatosis, suggesting iron storage in the liver may precipitate malignant transformation in this species, as alluded to by other authors.^{8,9}

PHOENICOPTERIDAE

Suborder Phoenicopteridae (flamingos) had 265 representatives and 13 tumors (4.9%) (see Table 20.2.2), suggesting that the overall prevalence of neoplasia in the family/suborder is about average. Interestingly, liver tumors accounted for slightly less than half of the tumor submissions (see Table 20.2.1), suggesting that hepatic neoplasia may be over-represented in captive flamingos. These birds typically store large amounts of iron in the liver^{7,15} and all the flamingos with hepatic neoplasia in this study had iron deposition; however, no overt changes were noted morphologically in relation to the iron, such as cirrhosis seen in mynahs, toucans or birds of paradise,^{3,7,15} so the significance of the iron deposition relative to the neoplasia is undetermined. Two flamingos had squamous cell carcinomas on the pads of the feet, and had previous and ongoing protracted episodes of bumblefoot, which may have predisposed to neoplastic transformation.

STRIGIFORMES

Order Strigiformes (owls) had 131 representatives and 13 tumors (9.9%) (see Table 20.2.2), suggesting that overall prevalence of neoplasia in this order may be relatively high compared to other orders in the study. Six of the owls were burrowing owls (*Athene cunicularia*), suggesting that these birds may have a higher than average prevalence of neoplasia. Three hepatocellular neoplasms were noted in this order, all in burrowing owls. Myelolipoma, an unusual neoplasm in birds, appears to be over-represented in owls, occurring in three cases in the study. All were intracoelomic neoplasms that were extensively invasive and of undetermined origin. Interestingly, the two affected snowy owls (*Nyctea scandiaca*) were pen mates for most of their lives and died from these tumors within months of each other. All three of the owls

with myelolipomas were from the same zoo.

SPHENISCIFORMES

Order Sphenisciformes (penguins) had 204 representatives and 11 tumors (5.4%) (see Table 20.2.2), about average compared to submissions from other avian orders. Over half of the tumor submissions (6, 55%) were squamous cell carcinomas, occurring in four different species of penguins. These data suggest that, in general, penguins may be predisposed to development of this form of neoplasm.

CICONIIFORMES

Order Ciconiiformes (herons, storks, ibises, spoonbills, New World vultures) (see Table 20.2.2) had 307 representatives and 11 tumors (3.6%), indicating the overall incidence of neoplasia in this order was slightly below the submitted average. Eight of the tumor submissions were in roseate spoonbills (*Ajaia ajaja*) and seven of the tumors in this species were focal or multicentric renal adenomas, a tumor that was otherwise uncommonly encountered in avian submissions. These data indicate that roseate spoonbills may be predisposed to developing this form of neoplasia. Although benign, four of these tumors contributed directly to the cause of death.

MISCELLANEOUS ORDERS

Several orders had no apparent trends in neoplastic disease. These include Columbiformes (pigeons, doves), Gruiformes (cranes, related species), Falconiformes (eagles, hawks, falcons, Old World vultures), Charadriiformes (shorebirds), Coraciiformes (kingfishers, motmots, hornbills), Cuculiformes (turacos, cuckoos), Piciformes (woodpeckers, toucans, barbets), Struthioniformes (ratites), Coliiformes (mousebirds) and Pelecaniformes (pelicans, cormorants). Two birds of undetermined species also had neoplastic processes. Four orders, Gaviiformes (grebes, loons), Procellariiformes (fulmars), Caprimulgiformes (tawny frogmouths) and Apodiformes (hummingbirds) were represented in low numbers and had no neoplastic processes (see Table 20.2.2).

References and Suggested Reading

- Biggs PM: Lymphoproliferative disease of turkeys. *In* Calnek BW (ed): *Diseases of Poultry*. Ames, Iowa State Univ Press, 1997, pp 485-489.
- Calnek BW, Witter RL: Marek's Disease. *In* Calnek BW (ed): *Diseases of Poultry*. Ames, Iowa State Univ Press, 1997, pp 369-413.
- Gosselin SJ, Kramer LW: Pathophysiology of excessive iron storage in mynah birds. *J Am Med Assoc* 183(11):1238-1240, 1983.
- Graham DL: Internal papillomatous disease: A pathologist's view of cloacal papillomas – and then some! *Proc Assoc Avian Vet*, 1991, pp 141-143.
- Johne R, et al: Herpesviral, but no papovaviral sequences, are detected in cloacal papillomas of parrots. *Arch Virol* 147(10):1869-1880, 2002.
- Latimer KS: Oncology. *In* Ritchie BW, Harrison GJ, Harrison LR (eds): *Avian Medicine: Principles and Application*. Brentwood, TN, HBD Int'l, Inc, 1999, pp 640-672.
- Lowenstine LJ, Munson L: Iron overload in the animal kingdom. *In* Fowler ME, Miller RE (eds): *Zoo and Wild Animal Medicine. Current Therapy 4*. Philadelphia, WB Saunders Co, 1999, pp 260-268.
- Macwhirter P: Passeriformes. *In* Ritchie BW, Harrison GJ, Harrison LR (eds): *Avian Medicine: Principles and Application*. Brentwood, TN, HBD Int'l, Inc, 1999, pp 1172-1199.
- Panigrahy B, Senne DA: Diseases of mynahs. *J Am Vet Med Assoc* 199(3):378-381, 1991.
- Payne LN, Fadly AM: Leukosis/sarcoma group. *In* Calnek BW (ed): *Diseases of Poultry*. Ames, Iowa State Univ Press, 1997, pp 414-466.
- Reece RL, et al: Common necropsy findings in captive birds in Victoria, Australia (1978-1987). *J Zoo Wildl Med* 23(3):301-312, 1992.
- Reece RL: Tumors of unknown etiology. *In* Calnek BW (ed): *Diseases of Poultry*. Ames, IA, Iowa State Univ Press, 1997, pp 485-489.
- Styles DK, Phalen DN, Tomaszewski EK: Elucidating the etiology of avian mucosal papillomatosis in psittacine birds. *Proc Assoc Avian Vet*, 2002, pp 175-178.
- Sundberg JP, et al: Cloacal papillomas in psittacines. *Am J Vet Res* 47(4):928-32, 1986.
- Ward RJ, et al: Hepatic iron overload in birds: Analytical and morphological studies. *Avian Pathol* 17:451-464, 1988.
- Witter RL: Reticuloendotheliosis. *In* Calnek BW (ed): *Diseases of Poultry*. Ames, Iowa State Univ Press, 1997, pp 467-484.

